

Research Article

Open Access

Accuracy of Cone Beam Computed Tomography as a Pre-Operative Tool to Assess Maxillary Molar Furcation Involvement

Kranti. K¹, Mani R¹, Ashutosh R. Tervankar²

¹Department of Periodontology, Faculty of Dental Sciences, M.S Ramaiah University of Applied Sciences, Bangalore, India

²Post Graduate Student, Department of Periodontology, M.S Ramaiah University of Applied Sciences, Bangalore, India

Corresponding Author: Kranti K, Department of Periodontology, Faculty of Dental Sciences, M.S Ramaiah University of Applied Sciences, Bangalore, India. Tel: 09880382393, E-mail: drkrantireddy@gmail.com

Citation: Kranti. K et al. (2015), Accuracy of Cone Beam Computed Tomography as a Pre-Operative Tool to Assess Maxillary Molar Furcation Involvement. Int J Dent & Oral Heal. 1:1, 1-6. DOI: [10.25141/2471-657X-2015-1.0033](https://doi.org/10.25141/2471-657X-2015-1.0033)

Copyright: ©2015 Kranti K et al. This is an open-access article distributed under the terms of the Creative Commons Attribution License, which permits unrestricted use, distribution, and reproduction in any medium, provided the original author and source are credited

Received: October 31, 2015; **Accepted:** November 06, 2015; **Published:** December 23, 2015

Abstract

Aim: The objective of this study was to investigate the use of cone beam computed tomography (CBCT) in assessing furcation involvement (FI).

Methods: The study group comprised of 17 patients diagnosed as generalized chronic periodontitis. A total of 20 first and 12 second maxillary molars with 96 furcation entrances were included. The degree of FI obtained by periodontal probing was compared with the degree estimated from CBCT imaging.

Results: FI was observed in all 96 furcation entrances clinically, while a FI degree I–III was found in 75 sites according to the CBCT. Overall, only 28% of the clinical findings were confirmed in the CBCT, while 30.2% were overestimated and 41.7% revealed an underestimation

Conclusion: Employing CBCT for treatment in furcation involved maxillary molars will help to verify the clinical diagnosis and prevent redundant surgical intervention.

Keywords : Cone Beam Computed Tomography, Furcation involvement, Periodontal probing

Introduction:

Periodontal disease is characterized by periods of disease activity followed by periods of latency. Periodontal disease progression causes attachment loss, bone crest resorption, alveolar bone loss, and consequently tooth mobility. These characteristics grant importance to the use of imaging methods in the detection of such alterations. Further, it is important to use side by- side clinical and radiographic examinations to obtain a more accurate diagnosis¹

Periodontists commonly face the difficulty of accurately assessing, diagnosing, providing prognosis and treating furcation's that are affected by periodontal disease, molars being highly damaged by this disease.² Treating a furcation involvement (FI) requires a thorough diagnosis comprising of the estimation of the degree of horizontal and vertical FI, the assessment of the residual inter- and periradicular bone, and the evaluation of the root morphology with the length of the root trunk and the degree of root separation. Diagnosis is generally based on probing pocket depth (PPD), probing attachment level (PAL), probing of the furcation entrance

and periapical radiographs.³ However, analysing FI accurately is not feasible in many instances due to limited access, morphological variations and measurement errors. An ultimate diagnostic tool in verifying clinical and radiographic assessments is an explorative open flap procedure⁴.

Among two-dimensional (2D) radiographic diagnosis methods, bitewing and periapical radiographs are the most suitable because they are easily acquired, cheap and provide high-resolution images.^{5,6} However, these methods are limited by overlapping anatomical structures,^{7,8} difficulty in standardization^{5,8}, by underestimating the size and occurrence of bone defects⁹ and an unfavourable orientation of the x ray beam.

To overcome these limitations, dental cone beam computed tomography (CBCT) has been introduced to Periodontology, and its diagnostic accuracy in the detection and the quantification of periodontal defects in invitro settings has been confirmed^{7,8, 10, 11}. This radiographic tool provides good

imaging quality with less radiation exposure than conventional CT devices^{12,13}. CBCT systems differ in features such as field of view (FOV), voxel size and image detection system. The FOV is ideally adjustable in height and width to limit radiation exposure to the region of interest only. CBCT units can produce sub-millimeter voxel resolutions ranging from 0.4 mm to as small as 0.08 mm¹⁴.¹⁵. The clarity of CBCT images is affected by artefacts, noise and poor soft-tissue contrast. Disadvantages such as beam-hardening artefacts, streak artefacts and scattered radiation, though occur to a lesser extent in CBCT compared to conventional CT are still its limitations affecting diagnostic accuracy.^{16,17,18}

Recent in vitro studies have shown better precision in the evaluation of bone changes associated with periodontal disease using CBCT when compared to conventional and digital radiography, mainly in the visualization of the furcation involvement of the maxillary molar.^{7,11} However, in vivo studies are still scarce. Therefore, the objective of this study was to investigate the use of cone beam computed tomography (CBCT) in assessing furcation involvement (FI).

Materials and methods:

The study group comprised of 17 patients (3 women and 14 men) with an age range of 41–80 yrs and diagnosed as generalized chronic periodontitis. Patients were recruited from the Department of Periodontology, Faculty of Dental Sciences, MSRUAS. A total of 20 first and 12 second maxillary molars with 96 furcation entrances were included. Complete clinical and radiographic examinations were performed and instructions for supragingival plaque control were given. Patients with at least one maxillary molar with persisting increased PPD (≥ 6 mm) and/or advanced FI, defined as horizontal inter-radicular loss of periodontal tissues of degree II or III, were considered for possible inclusion in the study and informed consent were being taken. Periodontal surgery was considered for sites with PPD ≥ 6 mm. The patients with furcation caries, metal crowns in the CBCT irradiation area or silver amalgam fillings near the alveolar crest and women who were pregnant or lactating were not included in the study.

Probing Pocket Depth (PPD) and Probing Attachment Level (PAL) were measured to the nearest millimeter at six sites (mesiobuccal, buccal, distobuccal, distopalatal, palatal and mesiopalatal) of the selected maxillary molars using a periodontal probe (UNC- 15; HU-Friedy). The cemento-enamel junction or a stable reference point, such as the restoration margin, were used as the reference for the PAL measurements. FI were measured at three sites (buccal, mesiopalatal and distopalatal) of the suspected maxillary molars

using a curved scaled Nabers probe marked at 3mm intervals (HU-Friedy) without elevation of a soft tissue flap. The defect was characterized according to Hamp et al. (1975) using a modification of the furcation classification degree II, which was divided into degrees II and II–III.¹⁹ Degree 0 : furcation not accessible with a periodontal probe ,Degree I - horizontal loss of periodontal tissue support up to 3mm, Degree II : horizontal loss of support exceeding 3 mm, but no more than 6mm, Degree II–III: horizontal loss of support exceeding 6 mm, but no detectable “through and through” destruction and Degree III : horizontal “through and through” destruction of the periodontal tissue in the furcation.

Tooth mobility was measured moving the tooth between two rigid instruments and classified according to the Miller’s index (Miller 1938). Pulp sensibility was tested using Endo ice. Periapical radiographs were made from maxillary molars using intra-oral dental films, a film-holder with 90 degree angulation for the parallel technique, and standardized exposure time and X-ray tube voltage.

The CBCTs were performed in the distal maxillary area using the high resolution imaging system CS 9300C (Carestream, Rochester, USA) with a cylindrical volume of 5 cm x 5 cm to 13.5 cm x 17 cm, and settings in the range of 60–90 kV and 5–8 mA. Voxel size of ranging from 300-500 μ m. Exposure of 1982 mGy/cm².

The CBCT images of each tooth included were analysed in the horizontal, sagittal and transversal sections. The software Trophy Dicom 6.4.0.4 (Carestream) with a linear measurement tool and a digital magnification lens was applied, which facilitates a continuous motion with the cursor in the 3D area visualized in the three planes on the computer screen.

FI was calculated in the horizontal plane measuring the distance between the outer root surface and the interradicular bone to the nearest millimeter. The degree of FI was graded as follows: Degree 0: no horizontal loss of periodontal tissue support, that is, no radiolucency in the furcation area, Degree I: horizontal loss of periodontal tissue support up to 3mm ,Degree II: horizontal loss of support exceeding 3 mm, but no “through and through” destruction and Degree III: horizontal “through and through” – destruction of the periodontal tissue in the furcation.

The degree II–III used for clinical estimations was not applied in the CBCT analysis due to the difference in the horizontal measures. The surrounding bony support of each maxillary molar root was assessed in the appropriate sagittal or transversal plane in the long axis of the root. Additional radiographic findings obtained from CBCT imaging were categorized as A, B, C, D & E. (Table: 1)

A: fusion of the whole or part of two adjacent roots indicated by the lack of a separating periodontal ligament	A1: fusion of mesiobuccal and distobuccal root A2: fusion of mesiobuccal and palatal root A3: fusion of distobuccal and palatal root
B: root proximity indicated by two separating periodontal ligaments	B1: root proximity at buccal roots B2: root proximity at mesiobuccal and palatal root B3: root proximity at distobuccal and palatal root
C: periapical lesion – localized radiolucency surrounding the apical region	C1: periapical lesion at the mesiobuccal root C2: periapical lesion at the distobuccal root C3: periapical lesion at the palatal root
D: combined periodontal-endodontic lesion – radiolucency around the apex communicating with the periodontal defect	D1: periodontal-endodontic lesion at the mesiobuccal root D2: periodontal-endodontic lesion at the distobuccal root D3: periodontal-endodontic lesion at the palatal root
E: other findings, such as root perforation, fenestration defects, missing buccal/palatal bone plate or overfill of the root canal	

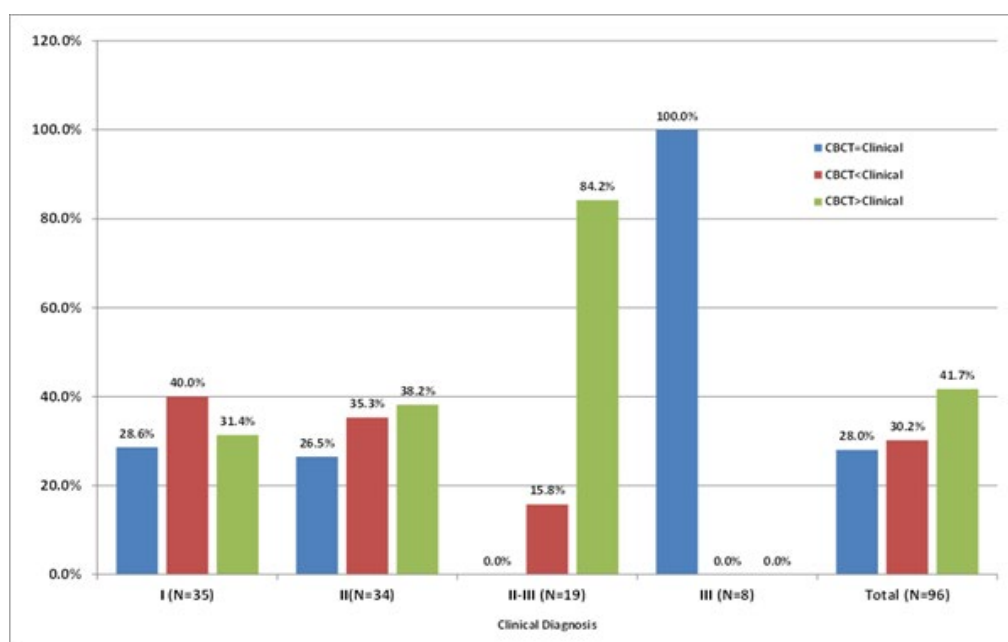
Table1: Categories of radiographic findings obtained from CBCT

The degree of FI obtained by periodontal probing was compared with the degree estimated from CBCT imaging. The clinical diagnosis was either confirmed, or a clinical over- or underestimation was revealed according to the CBCT data.

Results:

FI was observed in all 96 furcation entrances clinically, while a FI degree I–III was found in 75 sites according to the CBCT. Overall, only 28% of the clinical findings were confirmed in the CBCT, while 30.2% were overestimated (CBCT < clinical value) and 41.7% revealed an underestimation (CBCT > clinical value). Among the degree I FI, only 31.4% were underestimated, whereas

among the degrees II and II–III, the underestimation was 54.7%. Thus 38% of the clinical degree II furcations and the majority of the sites with clinical degree II–III (84%) were indeed degree III furcations. All clinically assessed degree III furcations were confirmed by the CBCT. An overestimation was observed in 40% of the clinical degree I furcations, which showed no radiolucency in the furcation area (degree 0 in CBCT)(Graph:1). The CBCT analyses revealed several additional findings such as root fusion or root proximity, which were not clearly discernible from the periapical radiographs. Combined periodontal-endodontic lesions were found affecting four teeth.



Graph I: Degree of furcation involvement obtained by periodontal probing compared with the degree obtained by CBCT imaging

Discussion:

The diagnosis and classification of furcation defects play an important aspect of a periodontal examination for treatment planning and prognosis of teeth. Owing to the limitations arising from the two-dimensional imaging obtained using conventional radiography, as well as the fact that considerable bone loss must occur prior to furcations being visible on radiographs, there are significant problems in determining the degree of furcation involvement.²⁰

In the current study, the established Hamp classification (1975) was modified by a sub-classification of FI degree II. This sub classification allowed to differentiate horizontal loss of periodontal tissue exceeding 6 mm without detectable “through and through” destruction.¹⁹ Also, three sections of the CBCT were used to analyse the furcation area and several morphological variations like root proximity or root fusion were detected. Owing to various morphological factors such as long root trunks, root concavities, bifurcation ridges and small furcation entrances, these contribute considerably to the difficulties in accurately assessing the FI clinically²¹. In addition, the CBCT enables the estimation of periapical lesions, or combined periodontal- endodontic lesions, the assessment of the existing root canal treatment, and the appraisal of the second mesiobuccal root canal.

In a population with generalized chronic periodontitis, a high incidence of 90% furcation involved maxillary molars have been reported²². FI was detected more frequently by conventional periapical radiographs than by clinical examination. 65% of FI teeth showed an agreement in the clinical and radiographic findings about FI, 22% were found by radiographic examination only and in 3% FI was detected by clinical examination alone²². The present

study reported that CBCTs facilitated an exact estimation of the FI, root proximities and root fusions.

When CBCT was compared to traditional two-dimensional intra-oral radiographs employing a digital CCD sensor, CBCT imaging was found to be superior for the imaging of defect shape, lingual or buccal furcation defects and furcation involvement, although more bone detail like bone quality, contrast and lamina dura was present on the CCD images^{1,11}. When CBCT was used, it detected and correctly classified 100% of furcation defects while digital radiographs detected only 56% of furcations¹.

In the present study, only 28% of the clinical findings were confirmed in the CBCT, while 30.2% were overestimated and 41.7% revealed an underestimation compared to CBCT. These results are similar to those seen in a study conducted by Walter C, et al 2009 where clinical measurements and conventional radiographs were used, it accurately predicted 27% of sites with furcation involvement, with 29% overestimating the furcation and 44% underestimating the defect compared to CBCT¹⁹. A study performed by Zappa U et al 1993 using intra-surgical horizontal probing and silicone impressions, found that 27% of true degree III furcations had been clinically underestimated, while overestimation was found in 18–21% of the degree I and 21% of the degree II furcations. The differences between the clinical and surgical assessments measured up to 9 mm, demonstrating a limited value of the clinical measures, which probably assigned inadequate treatment modalities²⁴. However, Eickholz P 1995 did not find significant differences between the pre-surgical and intra-surgical furcation classes and 14% of the clinical degree II involved furcations exposed a degree III intra-surgically²⁵.

A study by Zhong, J. S. et al 2010 evaluated the accuracy of

measurement of degree II furcation involvements in molars of dry mandibles by CBCT. They measured the vertical defect dimension, horizontal defect dimension and furcation entrance dimension of each FI by probing and CBCT and found that CBCT could provide precise and detailed 3D images of degree II furcation involvements in vitro²⁶. The detection of multiple periodontal defects (FIs and intra-bony defects) in two human skulls were compared between periapical radiographs and CBCT with the intra-oral situation following flap surgery. Periapical radiographs failed to detect FI in 44% of the cases, and only 20% of the FIs were correctly classified. In contrast, CBCT detected 100% FI and were correctly classified¹. Similar results were shown by Misch KA, et al 2006 where CBCT detected 100% of the artificially created intra-bony defects and only 67% were detected on periapicals⁸. Fuhrmann, R. A. et al 1997 reported only 21% of the artificial FIs were identified on periapicals and 100% through high-resolution CT²⁷. It has also been reported that CBCT imaging can be as high as 84% accurate in determining maxillary molar furcation defects compared to the surgical re-entry evaluation. However, CBCT may underestimate the extent of the furcation in around 15% of defects and overestimate the defect in only around 1% of defects. Furthermore, CBCT was found to be most accurate for assessing disto-palatal furcations, followed by buccal and mesio-palatal defects²⁸.

The drawback of all radiological techniques is the exposure to radiation of high-risk organs in the skull, such as the eye lens and thyroid gland. One of the advantages of the CBCT is that it requires less radiation exposure with a smaller volume that can be restricted to examine only the area of interest. However, the fundamental principle for diagnostic radiology abbreviated ALARA (as low as reasonably achievable) has to be followed, and additional CBCT procedures should be reserved for special cases²⁹. According to Walter C, et al 2009, CBCT facilitates a more detailed surgical treatment planning with a clear decision about respective interventions in the maxillary molar region, whereas clinical data and periapical radiographs led to two or even more different treatment options.¹⁹

Conclusion:

There is no data from a cost– benefit analysis available for this new application. Thus, the indication for additional CBCT imaging should be based not just on the clinical situation, but also on selection criteria derived from the overall periodontal and reconstructive treatment plan. Such criteria could be the need for retention of posterior abutment tooth with good prognosis, and patient's dental and/or medical history and compliance. The technical and financial effort involved and the additional radiation risk of the CBCT examination can be justified in patients for whom clinical measures and conventional radiographs cannot provide sufficient information. Employing CBCT for treatment in furcation involved maxillary molars will help to verify the clinical diagnosis and prevent redundant surgical intervention.

References:

1. Vandenberghe B, Jacobs R, Yang J. [Detection of periodontal bone loss using digital intraoral and cone beam computed tomography images: An in vitro assessment of bony and/or infrabony](#)

[defects. Dentomaxillofac Radiol](#) 2008; 37:252–60.

2. Qiao J, Wang S, Duan J, Zhang Y, Qiu Y, Sun C, Liu D. [The accuracy of conebeam computed tomography in assessing maxillary molar furcation involvement. J Clin Periodontol](#) 2014; 41: 269–74.

3. Kalkwarf, K. L. & Reinhardt, R. A. [The furcation problem. Current controversies and future directions. Dental Clinics of North America](#) 1988;32, 243–66.

4. Akesson, L., Ha°kansson, J. & Rohlin, M. () [Comparison of panoramic and intraoral radiography and pocket probing for the measurement of the marginal bone level. Journal of Clinical Periodontology](#) 1992;19, 326–32.

5. Jeffcoat MK. [Current concepts in periodontal disease testing. J Am Dent Assoc](#) 1994; 125: 1071–78.

6. Reddy MS. [Radiographic methods in the evaluation of periodontal therapy. J Periodontol](#) 1992; 63: 1078–84.

7. Mol A, Balasundaram A. [In vitro cone beam computed tomography imaging periodontal bone. Dentomaxillofac Radiol](#) 2008; 37: 319–24.

8. Misch KA, Yi ES, Sarment DP. [Accuracy of cone beam computed tomography for periodontal defect measurements. J Periodontol](#) 2006; 77: 1261–66.

9. Eickholz P, Kim T-S, Benn DK, Staehle HK. [Accuracy of radiographic assessments of interproximal bone loss. Oral Surg Oral Med Oral Pathol Oral Radiol Oral Endod](#) 1998; 85: 99–106.

10. Kasaj, A. & Willershausen, B. () [Digital volume tomography for diagnostics in periodontology. International Journal of Computerized Dentistry](#) 2007;10, 155–68.

11. Vandenberghe, B., Jacobs, R. & Yang, J. [Diagnostic validity \(or acuity\) of 2D CCD versus 3D CBCT-images for assessing periodontal breakdown. Oral Surgery, Oral Medicine, Oral Pathology, Oral Radiology and Endodontics](#) 2007; 104, 395–401.

12. Mozzo, P., Procacci, C., Tacconi, A., Martini, P. T. & Andreis, I. A. [A new volumetric CT machine for dental imaging based on the cone-beam technique: preliminary results. European Journal of Radiology](#) 1998; 8, 1558– 64.

13. Schulze, D., Heiland, M., Thurmman, H. & Adam, G. [Radiation exposure during midfacial imaging using 4- and 16-slice computed tomography, cone beam computed tomography systems and conventional radiography. Dentomaxillofac Radiology](#) 2004; 33, 83–86.

14. White, S.C. (2008) [Cone beam imaging in dentistry. Health Physics](#) 95: 628–37.

15. J. Morita MFG. Corp. (2011) 3D Accuitomo 80® Brochure. www.jmorita-mfg.com/en/en_products_diagnostics_general_3d_accuitomo_80.htm

16. Scarfe, W.C., Farman, A.G. & Sukovic, P. [Clinical applications of cone-beam computed tomography in dental practice. Journal of the Canadian Dental Association](#) 2006;72: 75–80.

17. Sogur, E., Baks, B.G. & Grondahl, H.G. [Imaging of root canal fillings: a comparison of subjective image quality between limited cone- beam CT, storage phosphor and film radiography. International Endodontic Journal](#) 2007; 40: 179–85.

18. Patel, S. [New dimensions in endodontic imaging: Part 2. Cone beam computed tomography. International Endodontic Journal](#)

2009;42: 463–75.

19. Walter C, Kaner D, Berndt DC, Weiger R, Zitzmann NU. Three-dimensional imaging as a pre-operative tool in decision making for furcation surgery. *J Clin Periodontol* 2009; 36: 250–57.

20. Muller HP, Eger T. Furcation diagnosis. *J Clin Periodontol* 1999;26:485–498.

21. Al-Shammari, K. F., Kazor, C. E. & Wang, H. L. () Molar root anatomy and management of furcation defects. *Journal of Clinical Periodontology* 2001; 28, 730–40.

22. Ross, I. F. & Thompson, R. H. Jr. Furcation involvement in maxillary and mandibular molars. *Journal of Periodontology* 1980; 51, 450–54.

23. Vandenberghe B, Jacobs R, Yang J. Diagnostic validity (or acuity) of 2D CCD versus 3D CBCT-images for assessing periodontal breakdown. *Oral Surg Oral Med Oral Pathol Oral Radiol Endod* 2007;104:395–401.

24. Zappa, U., Grosso, L., Simona, C., Graf, H. & Case, D. Clinical furcation diagnoses and interradicular bone defects. *Journal of*

Periodontology 1993; 64, 219–27.

25. Eickholz, P. Reproducibility and validity of furcation measurements as related to class of furcation invasion. *Journal of Periodontology* 1995; 66, 984–89.

26. Zhong, J. S., Ou-Yang, X. Y., Liu, D. G. & Cao, C. F. Evaluation of the in vitro quantitative measurement of II degree furcation involvements in mandibular molars by conebeam computed tomography. *Beijing Da Xue Xue Bao* 2010; 42, 41–45.

27. Fuhrmann, R. A., Bucker, A. & Diedrich, P. R. Furcation involvement: comparison of dental radiographs and HR-CT-slices in human specimens. *Journal of Periodontal Research* 1997; 32, 409–418.

28. Walter C, Weiger R, Zitzmann NU. Accuracy of three-dimensional imaging in assessing maxillary molar furcation involvement. *J Clin Periodontol* 2010;37:436–441.

29. Farmann, A. G. (2005) ALARA still applies. *Oral Surgery Oral Medicine Oral Pathology Oral Radiology Endodontics* 100, 395–397.