



Case Report

ISSN 2471-657X

Amelogenesis Imperfecta in Primary Dentition- A Case of Full Mouth Rehabilitation

Revathy Viswanathan¹, Janak Harish Kumar^{*2}, Suganthi³

¹Department of Pedodontics, Tamilnadu Government Dental College and Hospital, Chennai, Tamilnadu, India

²Intern, Department of Pedodontics, Tamilnadu Government Dental College and Hospital, Chennai, Tamilnadu, India

³Department of Pedodontics, Tamilnadu Government Dental College and Hospital, Chennai, Tamilnadu, India

Abstract

The most common anomalies of dental hard tissues include hereditary defects of enamel. Amelogenesis imperfecta (AI) has been described as a complex group of hereditary conditions that disturbs the developing enamel and exists independent of any related systemic disorder. This clinical case report describes the diagnosis and management of hypoplastic amelogenesis imperfecta in a 5-year-old child. The treatment objectives were to improve aesthetics, improve periodontal health, prevent further loss of tooth structure, and improve the child's confidence. The treatment plan was to restore the affected teeth with full coverage restorations. Treatment involved placement of composite strip crowns on maxillary anterior teeth and stainless steel crowns on the posterior teeth followed by fluoride varnish application in the upper and lower arches. A 6-month follow-up showed great aesthetic and psychological improvements in the patient.

Keywords: Amelogenesis imperfecta, Deciduous dentition, Composite strip crowns, Stainless steel crowns

Corresponding author: Janak Harish Kumar

Intern, Department of Pedodontics, Tamilnadu Government Dental College and Hospital, Chennai, Tamilnadu, India .Tel: +919488383113,
E mail: janakhk@gmail.com

Citation: Janak Harish Kumar et al. (2018), Amelogenesis Imperfecta in Primary Dentition- A Case of Full Mouth Rehabilitation. Int J Dent & Oral Heal. 4:10, 166-169

Copyright: ©2018 Janak Harish Kumar et al. This is an open-access article distributed under the terms of the Creative Commons Attribution License, which permits unrestricted use, distribution, and reproduction in any medium, provided the original author and source are credited

Received: September 12, 2018

Accepted: September 24 , 2018

Published: October 25, 2018

Introduction

Hereditary defects of enamel are the most common anomalies of dental hard tissues. Amelogenesis imperfecta (AI) has been described as a complex group of hereditary conditions that disturbs the developing enamel and exists independent of any related systemic disorder^[1,2,3]. This inherited condition occurs due to disturbance in the enamel proteins during amelogenesis which results in abnormal enamel formation. This disturbance can lead to anomalies in enamel quantity, structure or composition^[4,5,6,7]. The mode of inheritance of AI can be either as autosomal dominant or autosomal recessive or X-linked^[8]. AI is the oldest known hereditary disorder affecting enamel observed in humans^[9]. This genetic disorder can affect any number of

teeth and can occur in both primary and permanent dentition which results in the teeth being small, pitted, grooved and fragile with discolouration^[10]. The incidence of AI ranges from 1:14,000 to as high as 1:700 children depending on the population under study and the diagnostic criteria employed^[11]. In children, hypoplastic type of AI is more prevalent^[12,13,14].

AI is classified into 4 major types and 14 subtypes depending on the clinical manifestation and genetic factors. The 4 main types are hypoplastic, hypocalcification, hypomaturational and hypomaturational-hypoplastic with taurodontism^[15]. Hypoplastic type occurs due to defect in the enamel matrix formation which is characterised by reduced thickness or amount of enamel^[16,17]. It can be localised or generalised but the calcification of the enamel is normal^[5]. Hypocalcified type occurs due to defect in the calcification of enamel wherein the enamel develops to normal thickness but is soft, friable and wears away easily from the underlying dentin^[16]. In hypomaturational type the enamel has normal thickness but compared to hypocalcified type it is harder shows mottling with opaque white to yellow-brown or red-brown discolouration and tends to chip away easily than wearing away^[2]. In hypomaturational-hypoplastic with taurodontism type, there is mixture of hypomaturational and hypoplastic defects with taurodontism^[17].

The common complications of AI regardless of the types are tooth sensitivity, poor aesthetics, decreased occlusal vertical dimension, difficulty in maintaining oral hygiene ultimately leading to decreased self confidence in cases involving anterior teeth^[12,18]. Other rare complications include multiple impacted teeth, congenitally missing teeth and anterior open bite^[19]. Treatment of AI becomes imperative not only for restorative and aesthetic reasons but also because of the psychological impact on the children it causes. We hereby report a case of Amelogenesis Imperfecta in primary dentition with full mouth rehabilitation.

Citation: Janak Harish Kumar et al. (2018), Amelogenesis Imperfecta in Primary Dentition- A Case of Full Mouth Rehabilitation. Int J Dent & Oral Heal. 4:10, 166-169

Case Report

A 5-year-old healthy female child reported to Department of Paediatric Dentistry with chief complaint of discoloured teeth present since eruption. Medical history was not contributory. Family history revealed that no family member or relative had such a presentation. The parent confirmed that the patient's social life was affected, and she was teased by her friends due to the poor appearance of her teeth. A comprehensive extraoral and intraoral clinical examination was done, and radiographs and photographs were taken. Clinical examination revealed patient had complete set of primary dentition. The enamel

was yellowish brown in colour, (Figure 1, 2) soft in consistency with attrited cuspal contour. Dental caries was seen in primary right upper second molar. (Figure 3) The radiographic examination revealed loss of enamel and discontinuity in the anterior teeth. Based on clinical and radiographic findings, the case was diagnosed as hypoplastic amelogenesis imperfecta.

The treatment objectives were to improve aesthetics, improve periodontal health, prevent further loss of tooth structure, and improve the child's confidence. The treatment plan was to restore the affected teeth with full coverage restorations.

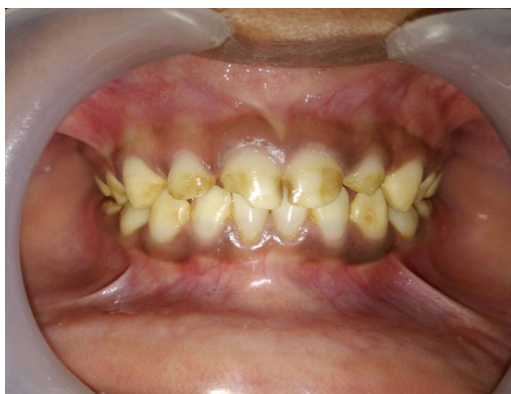

Figure 1: Pre-operative picture of occlusion

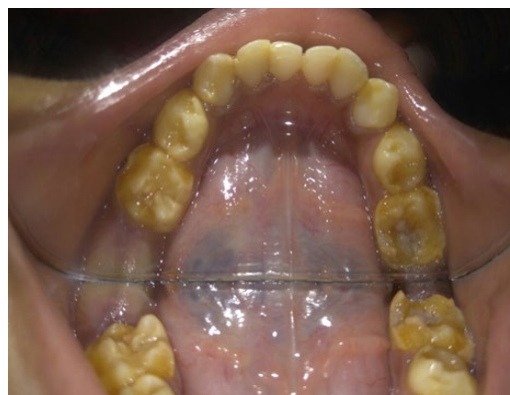

Figure 2: Pre-operative picture of mandible

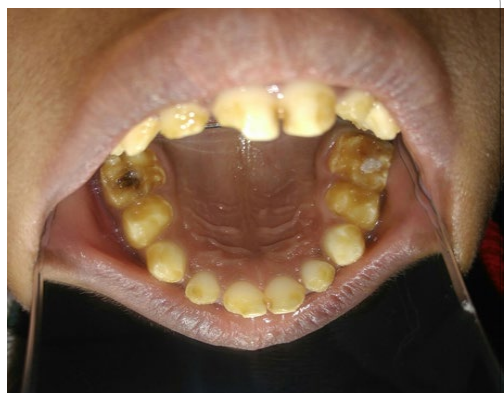

Figure 3: Pre-operative picture of maxilla

Anterior teeth were prepared to receive composite strip crowns.

(Figure 4) After the tooth preparation try-in was done with anterior strip crowns (3M ESPE) and size 3 was selected for all anterior teeth. Etching was done with 37% phosphoric acid on all the anterior teeth. Bonding agent (Te-Econom Bond, Ivoclar Vivadent) was then applied according to the manufacturer's instructions. Composite resin (Filtek Z350 by 3M ESPE) was packed into the strip crowns and was bonded to the prepared anterior teeth and was light cured. The composite strips were removed using a BP blade. Finishing and Polishing was

done. (Figure 5)

Dental caries was excavated from primary right upper second molar and vital pulp therapy was carried out. The Posterior teeth were prepared to receive stainless steel crowns. Stainless steel crowns (3M ESPE) were adapted on all primary molars and luted with type II Glass ionomer cement (GC). (Figure 6,7) Fluoride varnish application (Fluor Protector, Ivoclar Vivadent) was done in the upper and lower arches. Aesthetics and psychology of the patient had been greatly improved when the patient was followed up after 6 months.

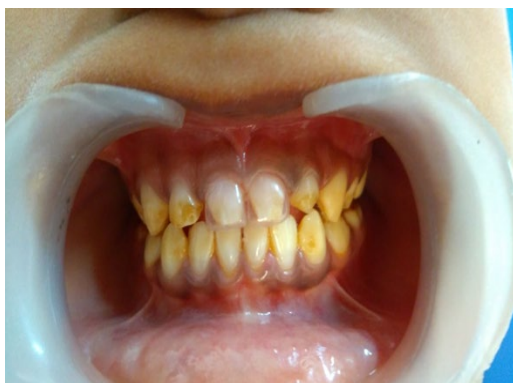

Figure 4: Preparation for placement of strip crowns

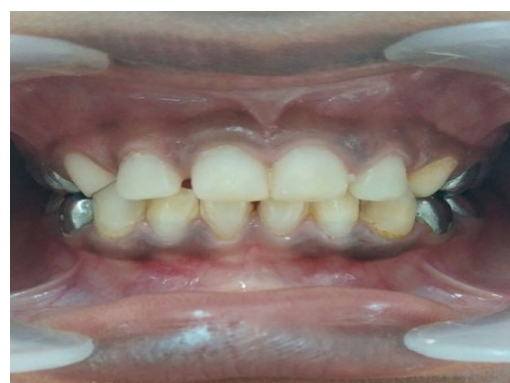

Figure 5: Placement of strip crowns

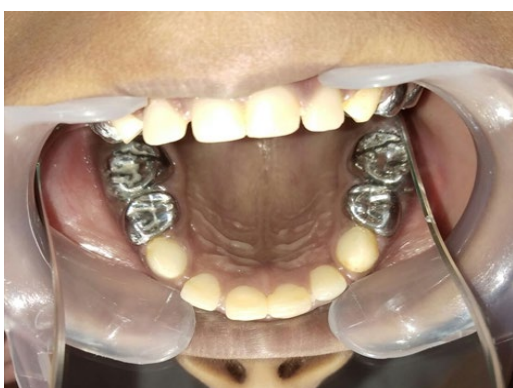


Figure 6: Placement of Stainless steel crowns on Maxillary molars

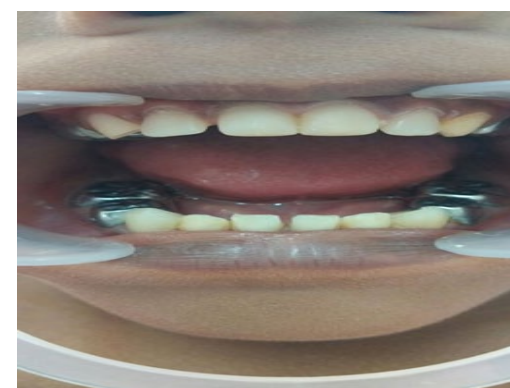


Figure 7: Placement of Stainless steel crowns on mandibular molars

Discussion

Amelogenesis imperfecta has many forms and the children are affected at a very early age. There are 3 stages in enamel formation: 1) the translation and secretion of an extracellular matrix, 2) mineralisation of the matrix, 3) matrix removal and crystalline growth or maturation of enamel^[5]. Any disruption in these stages results in Amelogenesis imperfecta^[20] with different subtypes of the condition arising from disruptions in the different phases of the stages^[21].

Hypoplastic AI occurs due to the disruption in the secretion of enamel matrix which is the first stage in enamel formation. It is characterised by local or generalised decrease in the thickness of the enamel with teeth being yellowish brown in colour, have a rough texture and wide spaces between them. Hypocalcified type occurs due to defect in the mineralisation of the enamel matrix which is the second stage in amelogenesis. The thickness of the enamel is almost normal but due to the deficient mineral content, the enamel is soft, friable, and subject to rapid wear. Hypomaturational type is due to defect in matrix removal which is the third stage in amelogenesis resulting in decreased mineral deposition and increased matrix retention. The enamel is of normal thickness but compared to the hypocalcified type, the enamel is harder, mottled, brown-yellow and tends to chip away rather than wearing away. These variants of AI may overlap clinically. The degree of mineralisation determines the various treatment options as thin or poorly mineralised enamel is difficult to bond to. Hypoplastic type has variable mineral content while the hypocalcified and hypomaturational type has low mineral content^[22]. AI is reported to be caused due to the

mutations in any of the following genes/locus AMELX, ENAM, MMP20, KLK4, FAM83H, WDR72, C4orf26 and FAM20A^[9].

The complications of AI may result in problems in mastication and aesthetics. The management of a patient with AI is dependent on many factors like age, socioeconomic status, the type and the severity of the condition. Preventive methods for AI in primary dentition include dietary advice, oral hygiene instructions and topical fluoride application^[23]. Four weeks of fluoride usage may result in reduction in dental sensitivity. With the possibility of the disorder presenting in permanent dentition too, it is the responsibility of the dentist to counsel the patient's parents about its effects in permanent dentition. If needed the parents can be encouraged to seek genetic counselling^[24]. The treatment of AI is multidisciplinary and it includes paedodontists, orthodontists, oral surgeons, and prosthodontists. For primary teeth the treatment options include use of glass ionomer cements, composite resins, full coverage restorations like stainless steel crowns, lab fabricated crowns, strip crowns, porcelain veneers. If anterior teeth cannot be restored and extractions are needed, an aesthetic bridge can be used. In case of multiple extractions, overdentures can be used too. Treatment of AI is a long process and cooperation from the child and motivation from the parents go a long way in success of the treatment.

References

1. Pinky SN, Shashikiran ND. [Amelogenesis imperfecta: Full mouth rehabilitation in deciduous dentition](#). Int J Clin Pediatr Dent. 2011 May;4(2):171.

2. Robinson FG, Haubenreich JE. [Oral rehabilitation of a young adult with hypoplastic amelogenesis imperfecta: A clinical report.](#) J Prosthet Dent 2006 Jan;95(1):10-13.
3. Lykogeorgos T, Duncan K, Crawford PJ, Aldred MJ. [Unusual manifestations in X-linked amelogenesis imperfecta.](#) Int J Pediatr Dent 2003 Sep;13(5):356-361.
4. de Souza-e-Silva CM, Parisotto TM, Steiner-Oliveira C, Gavião MB, Nobre-Dos-Santos M. [Oral rehabilitation of primary dentition affected by amelogenesis imperfecta: a case report.](#) J Contemp Dent Pract. 2010 May 1;11(3):71-7.
5. Ayers KM, Drummond BK, Harding WJ, Salis SG, Liston PN. [Amelogenesis imperfecta— multidisciplinary management from eruption to adulthood. Review and case report.](#) N Z Dent J. 2004; 100(4):101-4.
6. Crawford PJ, Aldred M, Bloch-Zupan A. [Amelogenesis imperfecta. Orphanet J Rare Dis.](#) 2007; 2:17.
7. Vitkov L, Hannig M, Krautgartner WD. [Restorative therapy of primary teeth severely affected by amelogenesis imperfecta.](#) Quintessence Int. 2006; 37(3):219-24.
8. Witkop CJ, Sauk JJ, Stewart RE, Prescott GH. Hereditary defects of enamel. Oral facial genetics. St Louis: Mosby. 1976; 151-226.
9. Zilberman U (2017) [Amelogenesis Imperfecta in Deciduous, Mixed and Permanent Dentition- Diagnosis and Treatment, Case Series.](#) JSM Dent Surg 2(1): 1009.
10. Sabatini C, Guzmán-Armstrong S. [A conservative treatment for amelogenesis imperfecta with direct resin composite restorations: A case report.](#) J Esthet Restor Dent 2009;21(3):161- 170.
11. Crawford PJ, Aldred MJ. [X-linked amelogenesis imperfecta. Presentation of two kindreds and a review of literature.](#) Oral Surg Oral Med Oral Path. 1992; 73(4):449-55.
12. Chosack A, Eidelman E, Wisotski I, Cohen T. [Amelogenesis imperfecta among Israeli Jews and the description of a new type of local hypoplastic autosomal recessive amelogenesis imperfecta.](#) Oral Surg Oral Med Oral Path. 1979 Feb 1;47(2):148-56.
13. Bäckman B, Holm AK. [Amelogenesis imperfecta: prevalence and incidence in a northern Swedish county.](#) Community Dent Oral Epidemiol. 1986 Feb 1;14(1):43-7.
14. Sundell S, Valentin J. [Hereditary aspects and classification of hereditary amelogenesis imperfecta.](#) Community Dent Oral Epidemiol. 1986 Aug 1;14(4):211-6.
15. Sengun A, Ozer F. [Restoring function and esthetics in a patient with amelogenesis imperfecta: A case report.](#) Quintessence Int 2002 Mar;33(3):199-204.
16. Singhal R, Pathak A, Goenka P. [Amelogenesis imperfecta with anterior open bite: A rare case report.](#) Int J Clin Pediatr Dent. 2011 Sep;4(3):245.
17. Ruby Kharkwal. [“Dental Rehabilitation of Amelogenesis Imperfecta in the Mixed Dentition”.](#) International Journal of Scientific Study. 2014;1(6):56-59.
18. Visram S, McKaig S. [Amelogenesis imperfecta— clinical presentation and management: A case report.](#) Dent Update 2006 Dec;33(10):612-616.
19. Markovic D, Petrovic B, Peric T. Case series: [Clinical findings and oral rehabilitation of patients with amelogenesis imperfecta.](#) Eur Arch Paediatr Dent. 2010; 11:4.
20. Cartwright AR, Kula K, Wright TJ. [Craniofacial features associated with amelogenesis imperfecta.](#) J Craniofac Genet Dev Biol. 1999;19(3):148-56.
21. Simmer JP, Hu JC. [Dental enamel formation and its impact on clinical dentistry.](#) J Dent Educ. 2001 Sep 1;65(9):896-905.
22. Collins MA, Mauriello SM, Tyndall DA, Wright JT. [Dental anomalies associated with amelogenesis imperfecta: a radiographic assessment.](#) Oral Surg Oral Med Oral Pathol Oral Radiol Endod. 1999 Sep 1;88(3):358-64.
23. Souza JF, Fragelli CM, Paschoal MA, Campos EA, Cunha LF, Losso EM, Cordeiro RD. [Noninvasive and multidisciplinary approach to the functional and esthetic rehabilitation of amelogenesis imperfecta: a pediatric case report.](#) Case Rep Dent. 2014;2014.
24. [Diagnosis and Treatment Planning in Dentistry \(Third Edition\)](#) Stephen J. Stefanac and Samuel P. Nesbit, [Chapter 3 – Evidence-based treatment planning: Assessment of risk, prognosis, and expected treatment outcomes, Page 72-103.](#) Elsevier publications.