

Volume 7 Issue 3,
March 2021

Copyright

©2021 Amr A. Ellithy et.al. This is an open access article distributed under the terms of the Creative Commons Attribution License, which permits unrestricted use, distribution, and reproduction in any medium, provided the original author and source are credited



Citation

Amr A. Ellithy et.al. (2021), Concentrated Growth Factors Versus Platelet Rich Fibrin in the Treatment of Intrabony Defects in Chronic Periodontitis. *Int J Dent & Ora Hea.* 7:3.

ISSN 2471-657X

Published by
Biocore Group I
www.biocoreopen.org/ijdo/ha/ha.php

Research Article

Concentrated Growth Factors Versus Platelet Rich Fibrin in the Treatment of Intrabony Defects in Chronic Periodontitis.

Amr A. Ellithy¹, Amal A. El-Hessy², Ebtessam A. El-Zefzaf²

¹ Assistant Lecturer at Oral Medicine, Periodontology, Oral Diagnosis and Radiology Department, Faculty of Dentistry, Tanta University, Egypt.

² Professors of Oral Medicine, Periodontology, Oral Diagnosis and Radiology Department Faculty of Dentistry, Tanta University, Egypt.

Corresponding author: Amr A. Ellithy

Assistant Lecturer at Oral Medicine, Periodontology, Oral Diagnosis and Radiology Department, Faculty of Dentistry, Tanta University, Egypt.

E-mail: perioking1@gmail.com

Article History: Received: March 03, 2021;
Accepted: March 25, 2021;
Published: March 30, 2021.

Abstract

Background: The ultimate goal of periodontal therapy is the regeneration of destructed periodontal tissues. There is a variety of treatment modalities available for periodontal regenerative therapy. The combination of various biomaterials and approaches has been approved to enhance a more favorable periodontal regeneration. There was little information about the role of platelet rich fibrin (PRF) and concentrated growth factors (CGF) combined with β -tri calcium phosphate and hydroxyapatite bone graft (β -TCP+HA) to enhance regeneration.

Objectives: The aim of this study was to evaluate and compare clinically and radiographically by cone beam computed tomography (CBCT) the effect of concentrated growth factors (CGF) versus platelet rich fibrin (PRF) both combined with β -tri calcium phosphate and hydroxyapatite bone graft (β -TCP+HA) in the treatment of intra-bony defects (ID) in patients with moderate to severe chronic periodontitis.

Materials and Methods: Twenty sites in patients diagnosed with moderate to severe chronic periodontitis based on clinical and periapical radiographic evaluation. A randomized controlled trial (RCT) was carried out on twenty intra-bony defects in the selected patients who fulfilled the inclusion criteria. After one month following phase I therapy sites were randomly classified to be treated with either CGF+ (β -TCP+HA) in group I or PRF+ (β -TCP+HA) in group II. The following clinical parameters Plaque Index (PI), Bleeding on Probing (BOP), Probing Pocket Depth (PPD) and Clinical Attachment Level (CAL) were recorded at baseline, 3 and 6 months after surgery. Radiographic evaluation by Cone Beam Computed Tomography (CBCT) was performed at baseline and 6 months postsurgical to evaluate bone level and bone density.

Results: Both groups showed statistically high significant improvement in all clinical parameters (PI, BOP, PPD, CAL) after 3 and 6 months postsurgical compared to baseline. Group I showed statistically significant reduction in PPD at 3 and 6 months postsurgical when compared to Group II. Statistically significant improvement in CAL gain at 3 and 6 months postsurgical when compared group I to group II. Radiographic assessment by CBCT analysis showed significant improvement in bone gain and bone density in both groups throughout the study period. Comparing the two groups, group I showed statistically significant reduction in Vertical Depth of defect (VD) when compared to group II at 6 months postsurgical while no statistically significant difference between the two groups in Alveolar Crest height (ACH), Width of Defect (WD), Area of Defect (AD) and Bone Density (BD).

Conclusion: Both treatment modalities resulted in clinical improvement as well as radiographic evidence of bone regeneration so these materials could be used successfully in the treatment of patients suffering from moderate to severe chronic periodontitis.

Keywords

Chronic Periodontitis, Intra-bony Defects, Platelet Rich Fibrin, Concentrated Growth Factors, β -Tri Calcium Phosphate, Hydroxyapatite Bone Graft.

Declaration of Conflicting Interest

The author[s] declared no potential conflicts of interest with respect to the research, authorship, and/or publication of this article.

Introduction

The bony defects can be developed by periodontal disease, tooth loss, trauma and infection. The goal of periodontal therapy is to eliminate inflammatory process, prevent the progression of periodontal disease and to regenerate the lost periodontal tissues. Various techniques have been developed in the past to truly regenerate the lost bony structures but complete and predictable reconstruction of periodontal tissues is still difficult to obtain.^[1]

To enhance regeneration, various adjunctive treatments to open flap debridement have been introduced. Four different approaches are used: 1) root conditioning 2) guided tissue regeneration (GTR)/barrier technique 3) filler techniques and 4) bio-molecular techniques (including enamel matrix proteins, platelet-rich plasma, and growth factors). Combinations of some of these approaches have been implemented and have been shown to improve gain of clinical attachment levels.^[2]

Augmentation of the osseous defect with bone grafts has become one of the most common surgical techniques in recent years. Autogenous bone graft is still the gold standard for bone grafting procedures due to their osteogenic, osteoinductive and osteoconductive properties. However, drawbacks with autogenous bone grafts include donor site morbidity, availability and unpredictable graft resorption. Similarly, although allografts and xenografts do not require additional surgical site but have the potential to disease transmission and provoke an immune response.^[3, 4]

Considering this, there has been substantial impetus to develop an ideal synthetic bone substitute for bone grafting procedures. The ideal synthetic bone graft should replicate the normal healing responses of autogenous bone by stimulating osteogenesis.^[5]

One of the synthetic bone graft material is the combination of Hydroxyapatite (HA)+ β -tricalcium phosphate (β -TCP) which has a very similar composition to natural bone and has shown perfect resorbability^[6], good biocompatibility, osteoconductivity in both animal and recently in human studies and has been widely used in the management of periodontal and peri-implant bone defects as well as of bone augmentation procedures.^[7]

Many commercial products are limited in that they only provide osteoconduction and osteointegration, exhibiting no other properties of natural bone. This can be overcome by adding growth factors and biomaterial, which act as mitogenic and chemotactic agents thus bring rapid regeneration. The introduction of bio-mimetic agents, such as enamel matrix derivatives (EMD), platelet-derived growth factor (PDGF), bone morphogenic proteins (BMP), platelet rich fibrin (PRF) and concentrated growth factors (CGF) has given new promise for better outcomes in periodontal treatment.^[8-10]

Platelets are known to release several growth factors which stimulate tissue regeneration. In order to accelerate healing of bone graft over the bony defect, platelets contain high quantities of growth factors, such as transforming growth factors β -1 (TGF β -1), platelet-derived growth factor (PDGF), epithelial growth factor (EGF), insulin growth factor-I (IGF-I) and vascular endothelial growth factors (VEGF), which stimulates cell proliferation and up regulates angiogenesis.^[11]

Sacco in 2006 developed the 3rd generation of platelet concentrate called concentrated growth factors (CGFs).^[12] Growth factors are proteins which regulate the complex processes of wound healing and play a main role on cell migration, cell proliferation and angiogenesis in tissue regeneration phase^[13]. Also play an important role in vascular maintenance. These growth factors are mainly located in blood plasma and platelets.

Given that to date, there is very little information about the use of CGF to enhance regeneration. Therefore, the aim of this study was directed towards clinical and radiographical comparison of potential regeneration effect of CGF versus PRF both combined with synthetic bone graft (β -TCP combined with hydroxyapatite bone graft) in the treatment of intra-bony defects in patients with chronic periodontitis.

Materials and Methods

Approval for this study was obtained from Research Ethics Committee (REC), Faculty of Dentistry, Tanta University.

A total of twenty sites of intra-bony defects in patients with moderate to severe chronic periodontitis were selected based on clinical and radiographic examination according to Armitage criteria^[14] and fulfilled the following inclusion criteria.

- Inclusion Criteria: Presence of intra-bony defects with a clinical attachment loss (CAL) \leq 4mm, no evidence of gingival recession, patients age ranged from 40 to 60 years old, optimal compliance as evidenced by no missed treatment appointments and a positive attitude towards oral hygiene.

• **Exclusion Criteria:** Patients with relevant medical conditions that may affect periodontal regeneration and periodontal surgery, patients with any disease or took any medication that affect normal number or function of platelets, smokers, pregnant or lactating women and patients in whom periodontal surgery had previously been carried out on the selected site.

Materials:

- Centrifuge device¹
- B-TCP combined with hydroxyapatite bone graft²
- Concentrated Growth Factors (CGF)
- Platelet Rich Fibrin (PRF)

I- Pretreatment Radiographical Assessment: Periapical radiographic evaluation was done to confirm the diagnosis. Cone Beam Computed Tomography (CBCT) was taken for every selected patient participated in this study.

The following calculations was made from the coronal, sagittal and 3 dimensional sections of CBCT pre surgical and 6 months post-surgical (**figure1**):

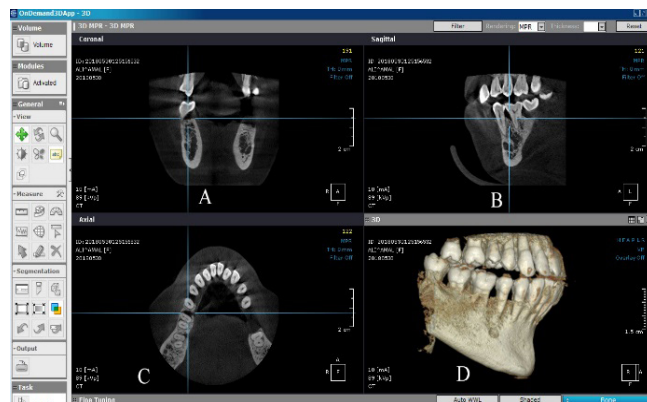


Figure 1 preoperative CBCT assessment of defect (A- coronal view, B-sagittal, C- axial and D- 3D views).

•Bone level

According to Misch et al.,^[15] bone level is measured as following:

Sagittal sections of CBCT:

- **Vertical depth of defect (VD):** the length from cemento enamel junction (CEJ) to the base of defect (BD). (**figure -2**)
- **Alveolar crest height (ACH):** the length from CEJ to the crest of bone adjacent to defect (AC). (**figure -2**)
- **Width of defect (WD):** the length of perpendicular line from (AC) to (CEJ-BD). (**figure -2**)
- **Area of the defect (AD):** the surface area drawn between (CEJ-BD-AC-CEJ). (**figure -3**)
- **Bone density (BD),** using Hounsfield unit: (**figure -4**)

Measured by region of interest (ROI) button in CBCT software between two fixed points (AC-BD).

All the CBCT scans were taken by a single trained technician pre- and post-surgery. The voltage, current, exposure time and detection field were kept constant for each patient at baseline and 6 months postsurgical. The sagittal and coronal sections were reconstructed after 6 months at the same axial slicing to that of the baseline. Duplicate measurements were always made and their mean considered as final values.

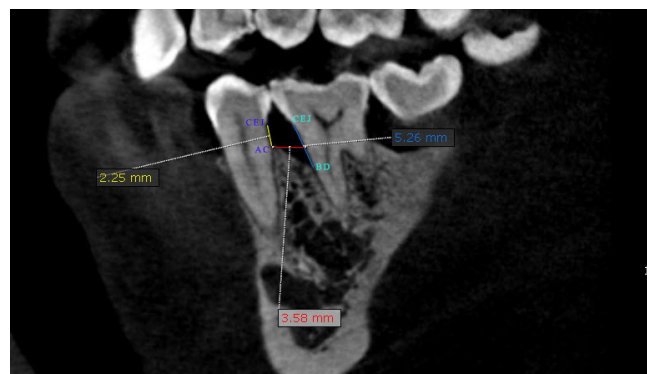


Figure 2 cone beam computed tomography at baseline – sagittal view - Vertical depth of defect- Alveolar crest height- Width of defect

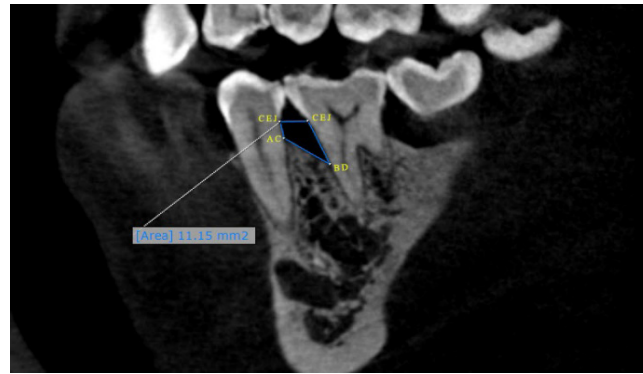


Figure 3 cone beam computed tomography at baseline – sagittal view -area of the defect

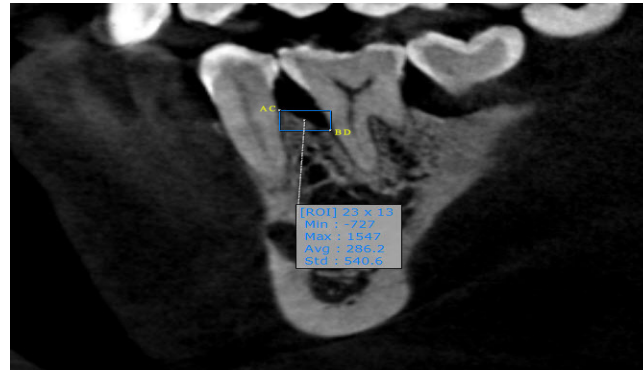


Figure 4 cone beam computed tomography at baseline – sagittal view -bone density by ROI.

II – Treatment Steps:

Phase I therapy: Scaling and root planing were done for all patients and as well as comprehensive oral hygiene instructions. Re- evaluation was conducted after one month to evaluate patient response to phase I therapy and to confirm the need for periodontal surgery.

Clinical Assessment include the following : Plaque index (PI),⁽¹⁶⁾ Bleeding on probing (BOP),⁽¹⁷⁾ Probing Pocket depth (PPD),⁽¹⁸⁾ Clinical attachment level (CAL).⁽¹⁸⁾

The above parameters were measured at baseline, 3 months and 6 months following surgical treatment.

Patient grouping: randomized controlled trial (RCT) was carried out on twenty intrabony defects in the selected patients who fulfilled the inclusion criteria after one month following phase I therapy. The twenty sites were classified using sealed envelope into two groups

- **Group I:** Ten sites were treated by CGF and β -TCP combined with hydroxyapatite bone graft.
- **Group II:** Ten sites were treated by PRF and β -TCP combined with hydroxyapatite bone graft.

CGF Preparation:

10 ml of blood was drawn from the patient then divided in 2 sterile tubes, one was non-coated and the other was glass coated test tube without anticoagulant. These tubes were placed oppositely in centrifuge device and then immediately centrifuged using a program with the following characteristics: 30 seconds acceleration, 2 minutes at 2700 rpm, 4 minutes at 2400 rpm, 4 minutes at 2700 rpm, 3 minutes at 3000 rpm and 36 seconds deceleration and stop. The centrifuge device was stopped after 2 minutes of centrifugation and the non-coated tube was removed which showed 2 layers, the upper layer was aspirated by a syringe and mixed with bone graft material to get sticky bone. The vacant tube was filled with water for weight balance and continued centrifugation. **Figures (5-A-B-C)**

At the end of the process, three blood fractions were obtained: a top layer represented by the serum (blood plasma without fibrinogen and coagulation factors, platelet poor plasma PPP), a middle layer represented by a very large and dense polymerized fibrin block containing the CGFs, white blood cells and stem cells and in the bottom RBC layer. **(figure 5 A-B-C)**

At time of surgery CGF layer was removed by a forceps and cut into uniform pieces of 1–2mm and mixed with bone graft and used to fill the defects in group I.

PRF Preparation:

10 ml of blood was drawn from the patient, then collected in a sterile glass test tube without any anti-coagulant. Immediately test tube was centrifuged using centrifuge machine at 3000 rpm for 12min. The result was a fibrin clot located in the middle of a mass of acellular plasma in the top and red cell layer in the bottom. **(Figure-6-A-B-C)**

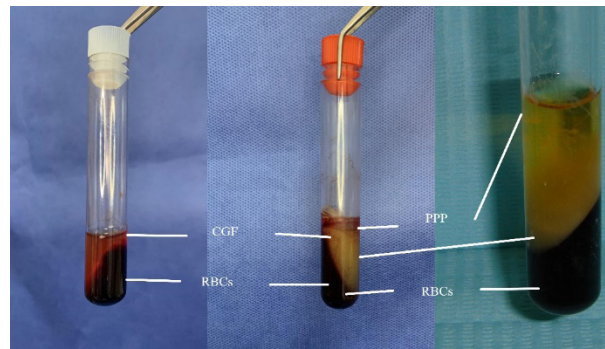


Figure 5 A different layers of Concentrated Growth Factors (CGF)



Figure 5-B β-TCP and HA bone graft

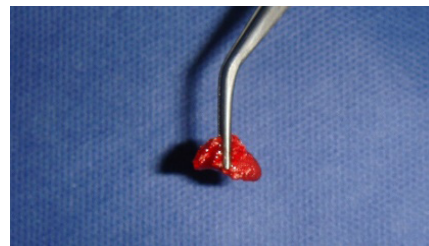


Figure 5-C CGF added to bone graft material to get sticky bone

The clot was removed from the tube with forceps and then cut into uniform pieces of 1~2mm, mixed with bone graft material and used to fill defects in group II. (Figure-6-A-B-C)

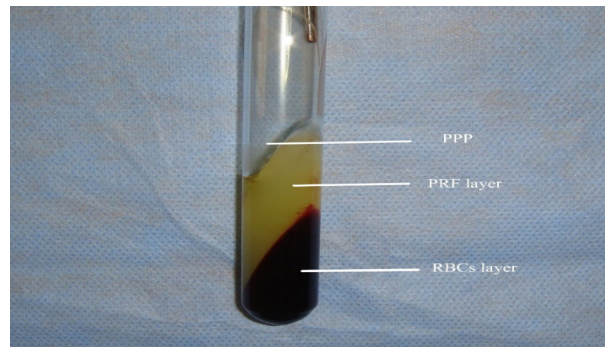


Figure 6 A different layers of Platelet Rich Fibrin (PRF)

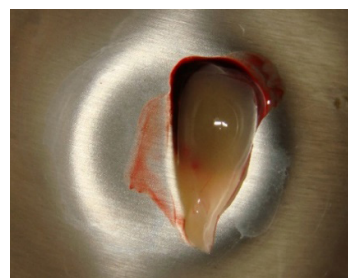


Figure 6 B PRF buffy coat layer

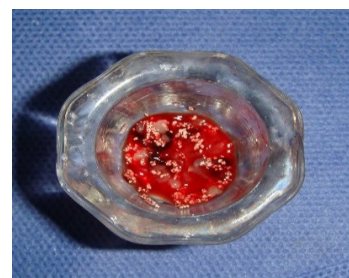

Figure 6 C PRF mixed with bone graft material

A-Surgical Procedure:

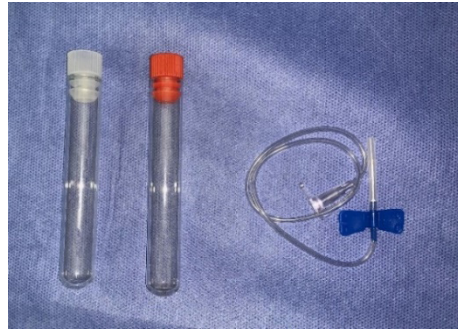
All surgical procedures were performed by the same operator.

- Prior to surgery patients were instructed to rinse with 0.1% chlorhexidine gluconate for 30 seconds.
- Anaesthesia was obtained by administration of 2% lidocaine 1:80,000 epinephrine. Buccal and lingual or palatal intrasulcular incisions were performed and full thickness mucoperiosteal flaps on the facial and lingual or palatal aspects of the involved sites were reflected. Soft tissue debridement was performed as well as thorough scaling and root planing of the exposed root surfaces.
- In group I intrabony defects were augmented by CGF mixed with bone graft material.
- In group II intrabony defects were augmented by PRF mixed with bone graft material.
- Closure was accomplished by using interrupted sutures with 4 zero silk suture and periodontal

dressings were placed.

Postoperative Care:

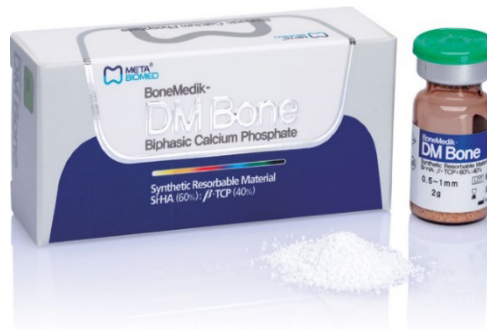- All subjects received postoperative instructions including rinsing with 0.1% chlorhexidine (twice daily for 2 weeks), if needed anti-inflammatory systemic medications (Brufen 400mg tablets) 3 times /day for 1 week was administered.
- Periodontal dressing and suture removal were performed after 10-14 days. Supportive periodontal therapy was performed monthly which includes periodontal evaluation (except for periodontal pocket depth which was measured after 3 months post operative), reinforcement of plaque control, scaling and root planing were carried out if needed and medical history was updated.



(A) blood withdrawal equipment and the blood collecting tubes.

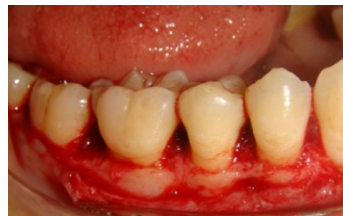

(B) centrifuge device

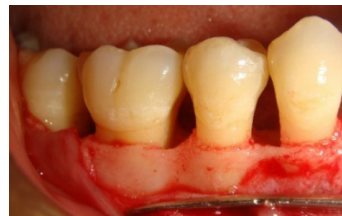

(C) Beta Tri Calcium Phosphate combined with hydroxyapatite bone graft (B-TCP+HA) bone graft (DM Bone).

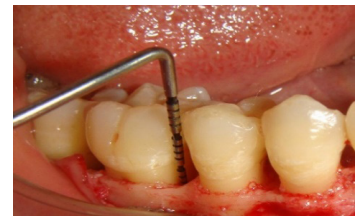Figure 7 Materials Used in the Study.



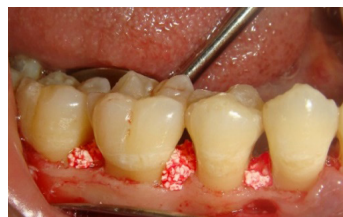(a) surgical site after flap elevation



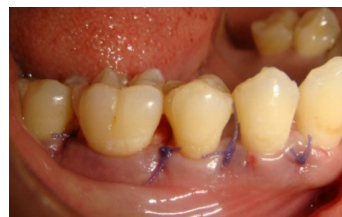(b) surgical site after debridement



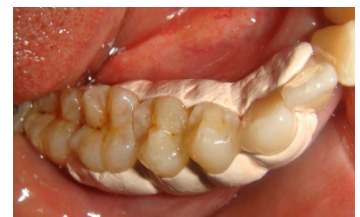(c) intra surgical measurement of Intra bony defect



(d) intra bony defects filled with CGF + DM Bone



(e) flap closure by interrupted suture



(f) periodontal dressing covering the defect site

Figure 8 surgical procedure in mandibular right intrabony defects in group I " CGF + B-TCP+HA"

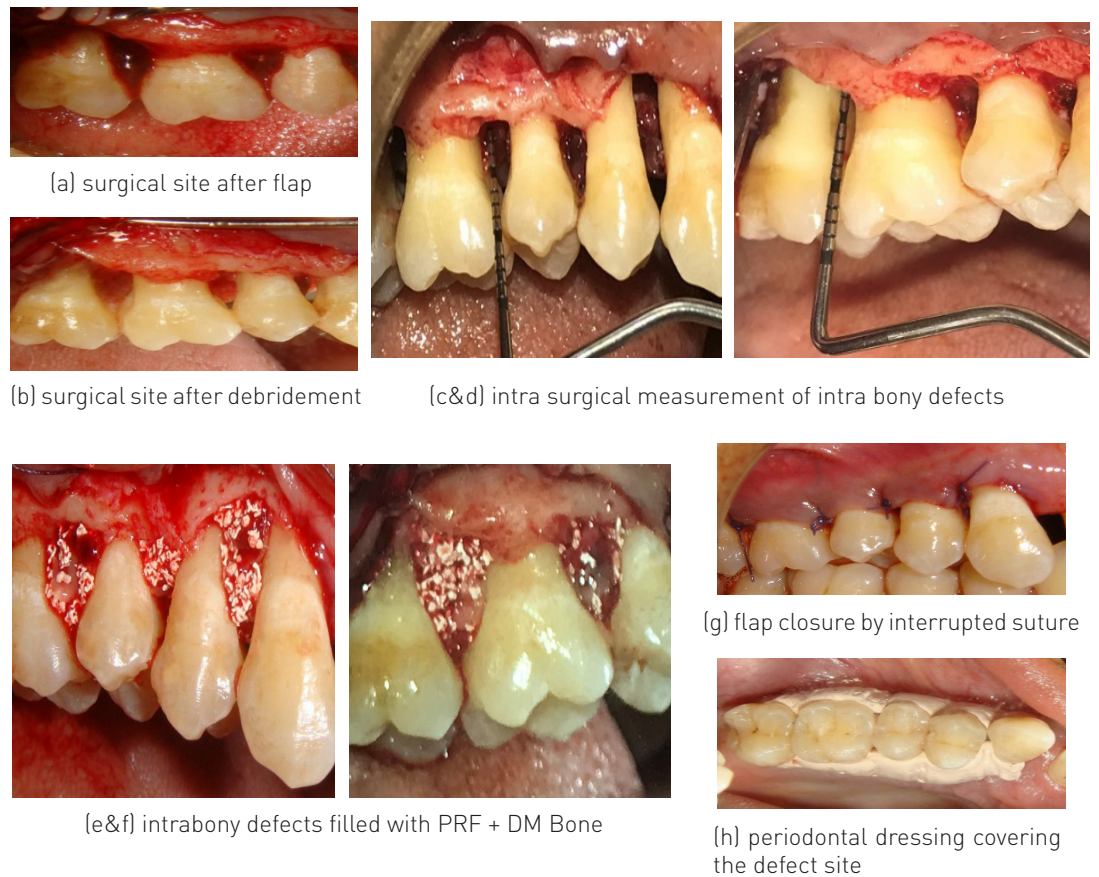


Figure 9 showing surgical procedure in maxillary right intrabony defects in group II "PRF + β-TCP+HA"

Results

I. Clinical Results:

Plaque Index Results (PI): using Mann Whitney test, it was found that the mean values of PI of group I and group II at baseline, 3 months and 6 months post treatment were (1.90 ± 0.88) versus (1.80 ± 0.63) , (1.50 ± 0.53) versus (1.10 ± 0.57) and (0.50 ± 0.53) versus (0.80 ± 0.92) respectively.

Comparing group I and II to each other there was no statistically significant difference between the two groups at all study periods baseline, 3 and 6 months postsurgical treatment. **table (1)**

Bleeding on Probing (BOP): both groups showed statistically significant decrease in BOP results when comparing baseline values to 3 and 6 months post surgically. Using Chi square test to Compare between group I and group II there was no statistically significant difference at all study periods baseline, 3 and at 6 months postsurgical treatment as $P > 0.05$. **table (2)**

Probing Pocket Depth (PPD) Results: using student t-test, it was found that the mean values of PPD of group I and group II at baseline, 3 months and 6 months post treatment were (6.70 ± 0.82) versus (6.90 ± 0.88) , (4.0 ± 0.47) versus (4.50 ± 0.53) and (2.40 ± 0.52) versus (3.20 ± 0.92) respectively. when comparing the two groups there was statistically significant difference between group I and group II at 3 and 6 months study intervals in favor of group I as $p \leq 0.05$. **table (3)**.

Clinical Attachment Level (CAL) Results: using Mann Whitney test, it was found that the mean values of CAL of group I and group II at baseline, 3 months and 6 months post treatment were (4.60 ± 0.84) versus (4.90 ± 0.88) , (2.7 ± 0.47) versus (3.20 ± 1.32) and (1.30 ± 0.52) versus (2.10 ± 1.73) respectively. The comparison showed that at 3 and 6 months study intervals, there was statistically significant difference in favor of group I ($p \leq 0.05$). **table (4)**

II. Radiographic Results:

1. **Vertical Depth of Defect (VD):** Comparing between the two studied groups, there was no significant difference at baseline values ($p=0.156$), while at 6 months results showed that there was a highly significant difference of the mean VD values in favor of group I as ($p=0.008$). **table (5)**

2. **Alveolar Crest Height Results (ACH):** When comparing the two groups there was no statistically significant difference at baseline and 6 months as $p=0.984$ and $p=0.214$ respectively. **Table (6)**

3. **Width of defect (WD) Results:** when comparing the two groups There was no statistically significant difference between group I and II at the baseline as $p=0.850$ and also when comparing the two groups at

6months postsurgical treatment as $P > 0.05$. **table (7)**

4. Area of the defect (AD) Results: when comparing mean AD values of group I and II to each other, the results showed that there was no significant difference between the two groups at baseline and 6 months study intervals as ($p=0.743$) and ($p=0.112$) respectively. **Table (8)**

5. Bone density (BD) Results: when comparing the two groups Using Mann Whitney test there was a statistically non-significant difference between group I and II at baseline and 6months postsurgical

Plaque index (PI)	Group I (n = 10)	Group II (n = 10)	U	p
Baseline	1.90 ± 0.88	1.80 ± 0.63	43.50	0.631
3 months	1.50 ± 0.53	1.10 ± 0.57	32.50	0.190
6 months	0.50 ± 0.53	0.80 ± 0.92	42.50	0.579

U: Mann Whitney test ; p: p value for comparing between the studied groups

Table 1 Comparison of mean values of plaque index between group I versus group II at baseline, 3 and 6 months postsurgical treatment.

Bleeding on probing (BOP)	Group I (n = 10)		Group II (n = 10)			FEp
	No.	%	No.	%		
Baseline						
Negative	0	0.0	0	0.0	-	-
Positive	10	100.0	10	100.0		
3 months						
Negative	6	60.0	5	50.0	0.202	1.000
Positive	4	40.0	5	50.0		
6 months						
Negative	8	80.0	8	80.0	0.00	1.000
Positive	2	20.0	2	20.0		

χ^2 : Chi square test ;FE: Fisher Exact ;p: p value for comparing between the studied groups

Table 2 Comparison of mean values of bleeding on probing between group I versus group II at baseline, 3 and 6 months postsurgical treatment.

Probing pocket depth (PPD)	Group I (n = 10)	Group II (n = 10)	t	p
Baseline	6.70 ± 0.82	6.90 ± 0.88	0.526	0.605
3 months	4.0 ± 0.47	4.50 ± 0.53	2.236*	0.038*
6 months	2.40 ± 0.52	3.20 ± 0.92	2.400*	0.031*

t: Student t-test; p: p value for comparing between the studied groups; *: Statistically significant at $p \leq 0.05$

Table 3 Comparison of mean values of probing pocket depth between group I versus group II at baseline, 3 and 6 months postsurgical treatment.

Clinical attachment level (CAL)	Group I (n = 10)	Group II (n = 10)	U	p
Baseline	4.60 ± 0.84	4.90 ± 0.88	39.0	0.436
3 months	2.7 ± 0.47	3.20 ± 1.32	25.0*	0.046*
6 months	1.30 ± 0.52	2.10 ± 1.73	23.0*	0.045*

U:Mann Whitney test;p:p value for comparing between the studied groups;*:Statistically significant at $p \leq 0.05$

Table 4 Comparison of mean values of clinical attachment level between group I versus group II at baseline, 3 and 6 months postsurgical treatment.

Vertical depth of defect (VD)	Group I (n = 10)	Group II (n = 10)	t	p
Baseline	6.03 ± 1.14	7.08 ± 1.90	1.495	0.156
6 months	3.64 ± 0.54	5.62 ± 1.84	3.269*	0.008*

t: Student t-test; p: p value for comparing between the studied groups; *: Statistically significant at $p \leq 0.05$

Table 5 Comparison of vertical depth of defect (VD) between group I and group II at baseline and 6 months postsurgical treatment.

Alveolar crest height (ACH)	Group I (n = 10)	Group II (n = 10)	t	p
Baseline	3.74 ± 1.19	3.75 ± 1.18	0.021	0.984
6 months	2.92 ± 1.22	3.61 ± 1.17	1.288	0.214

t: Student t-test; p: p value for comparing between the studied groups; *: Statistically significant at $p \leq 0.05$

Table 6 Comparison of Alveolar crest height (ACH) between group I and group II at baseline and 6 months postsurgical treatment.

Width of defect (WD)	Group I (n = 10)	Group II (n = 10)	t	p
Baseline	2.61 ± 0.38	2.57 ± 0.54	0.191	0.850
6 months	2.23 ± 0.61	2.45 ± 0.56	0.825	0.420

t: Student t-test; p: p value for comparing between the studied groups; *: Statistically significant at $p \leq 0.05$

Table 7 Comparison of Width of Defect (WD) between group I and group II at baseline and 6 months postsurgical treatment.

Area of defect (AD)	Group I (n = 10)	Group II (n = 10)	t	p
Baseline	12.28 ± 3.56	12.85 ± 4.11	0.332	0.743
6 months	7.94 ± 2.05	10.69 ± 4.64	1.712	0.112

t: Student t-test; p: p value for comparing between the studied groups; *: Statistically significant at $p \leq 0.05$

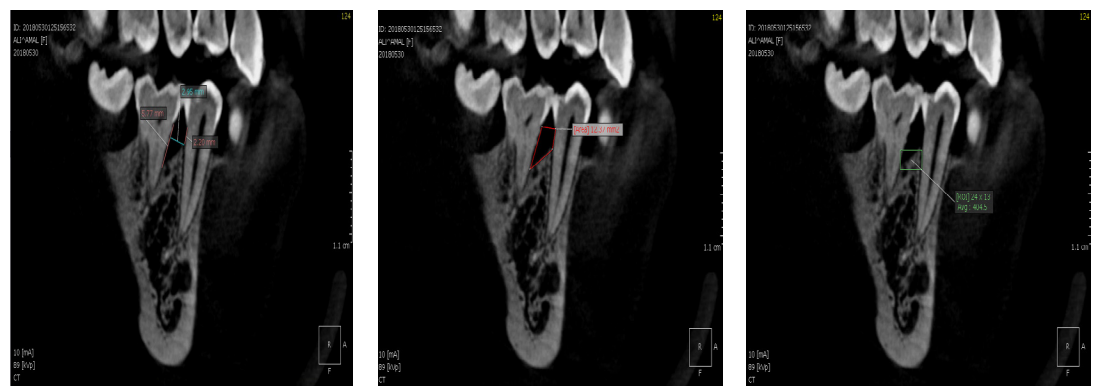
Table 8 Comparison of Area of Defect (AD) between group I and group II at baseline and 6 months postsurgical treatment.

Bone density (BD)	Group I (n = 10)	Group II (n = 10)	U	p
Baseline	512.2 ± 228.9	384.3 ± 129.7	30.50	0.143
6 months	983.9 ± 386.1	775.2 ± 416.7	34.50	0.247

U: Mann Whitney test ; p: p value for comparing between the studied groups; *: Statistically significant at $p \leq 0.05$

Table 9 Comparison of Bone Density (BD) between group I and group II at baseline and 6 months postsurgical treatment.

Baseline for mesial surface of first molar:

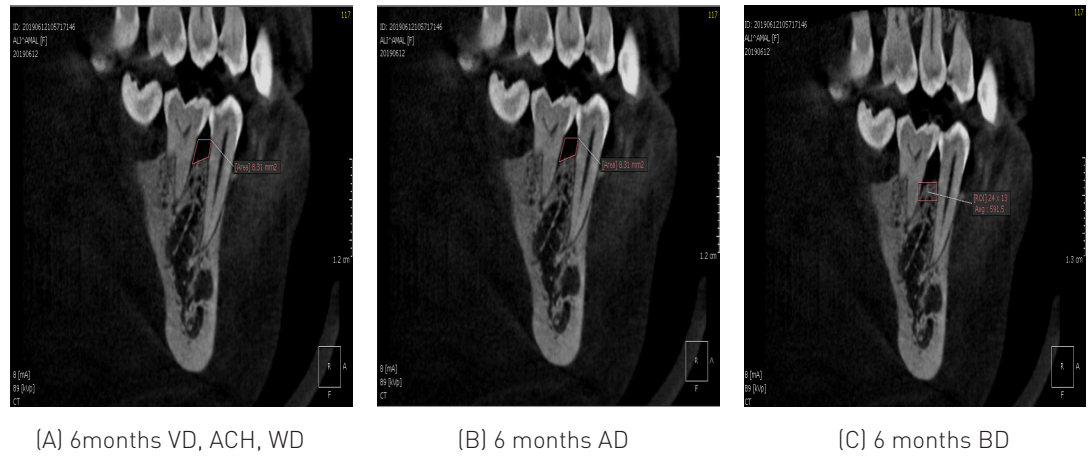


(A) Baseline VD, ACH, WD

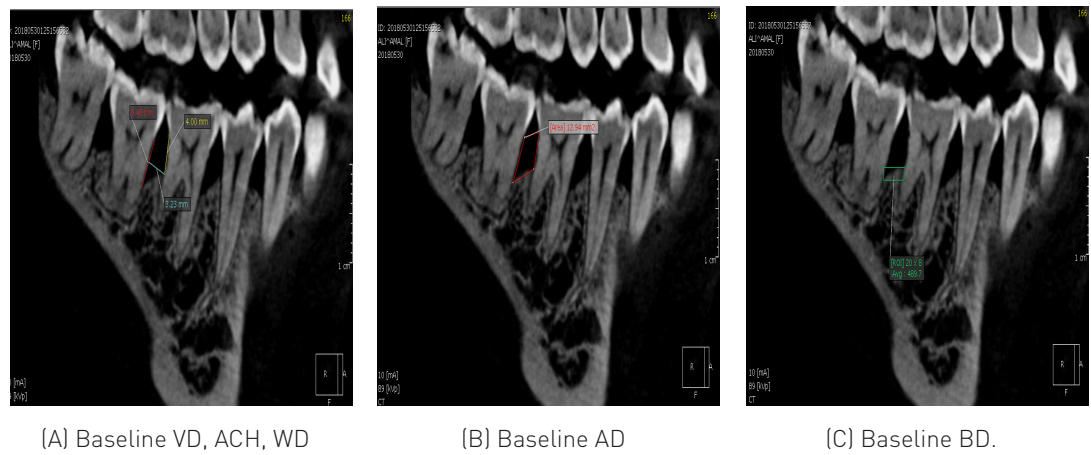
(B) Baseline AD

(C) Baseline BD

Post 6 months for mesial surface of first molar:



Baseline for mesial surface of second molar:



Post 6 months for mesial surface of second molar:

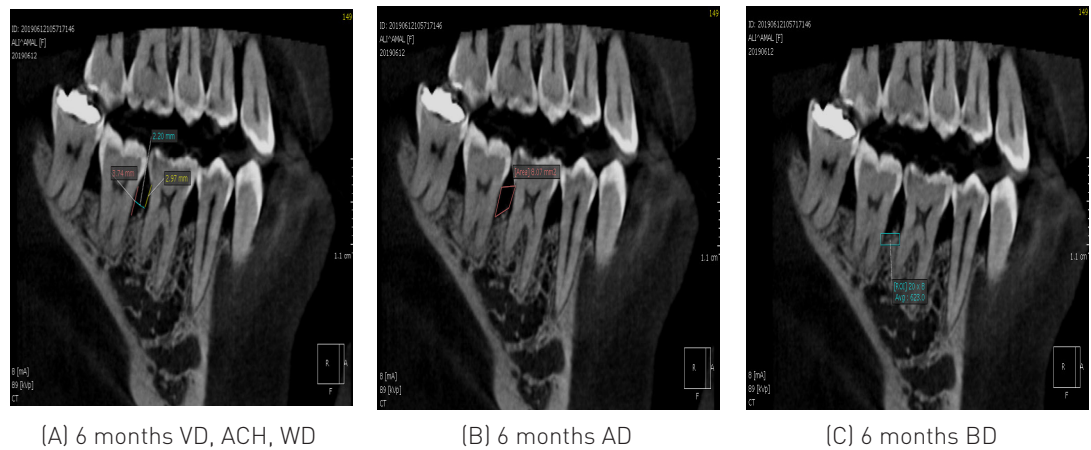
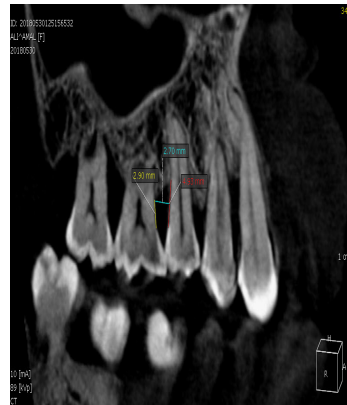
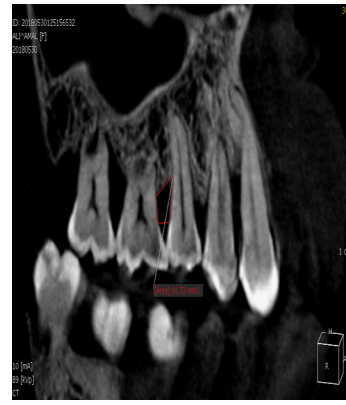

Figure 10 The software layout displaying the baseline,6 months digital CBCT images showing measurements of VD, ACH, WD, AD and BD for lower right intrabony defects in first and second molar in group I.

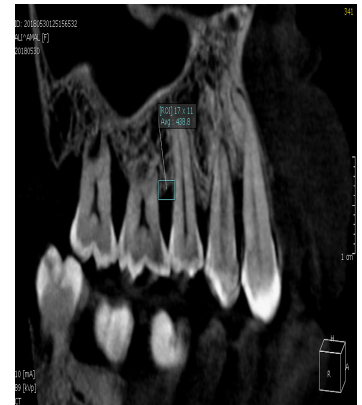
Baseline for second premolar:



(A) Baseline VD, ACH, WD

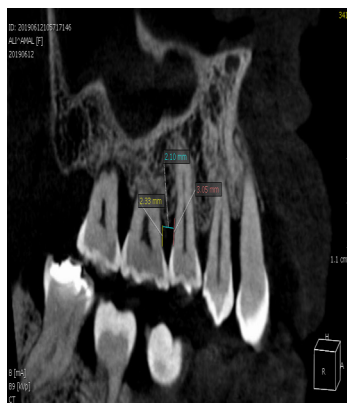


(B) Baseline AD

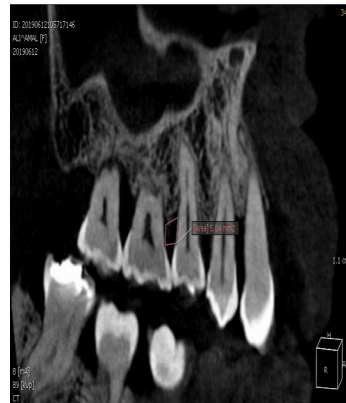

(C) Baseline BD

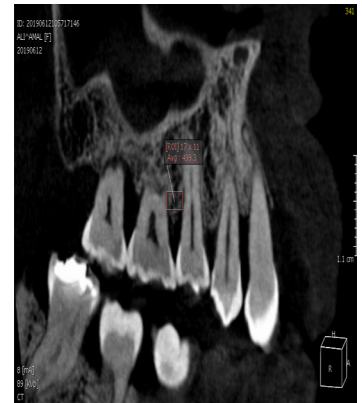
Post 6 months for second premolar:



(A) 6 months VD, ACH, WD

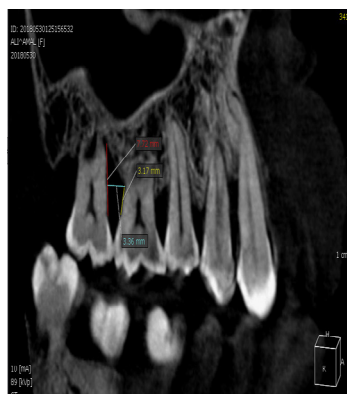


(B) 6 months AD

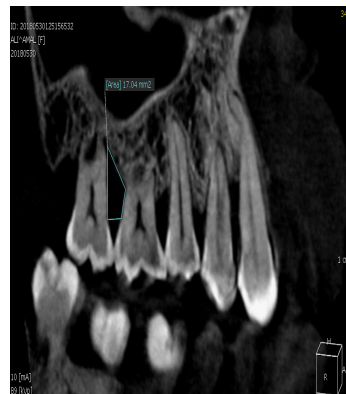


(C) 6 months BD

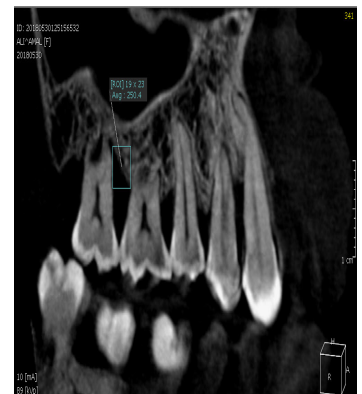
Baseline for second molar:



(A) Baseline VD, ACH, WD



(B) Baseline AD



(C) Baseline BD.

Post 6 months for second molar:

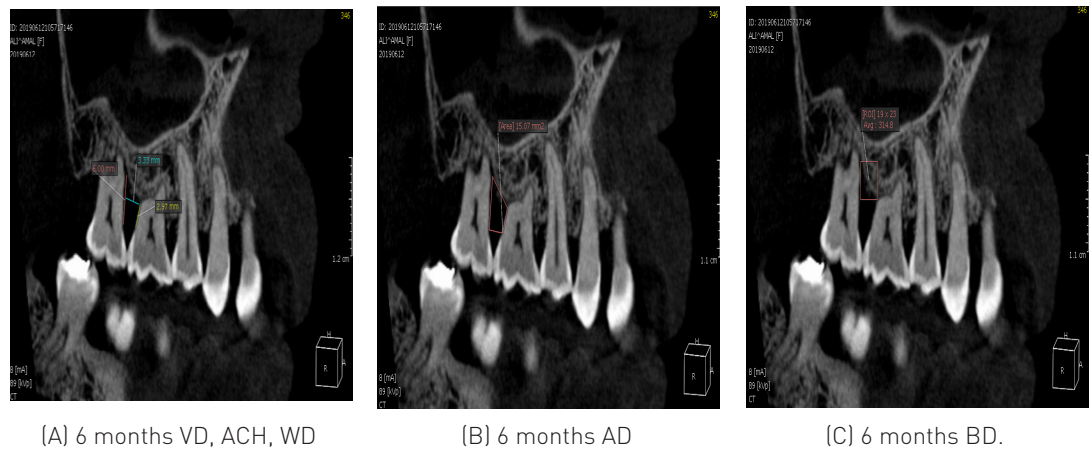


Figure 11 The software layout displaying the baseline, 6 months digital CBCT images showing measurements of VD, ACH, WD, AD and BD maxillary right intrabony defects in distal surface of second premolar & in mesial surface of second molar in group II.

treatment ($p=0.247$). table (9)

Discussion

The present study was carried out to assess and compare clinically and radiographically by using Cone Beam Computed Tomography (CBCT) the regenerative effect of concentrated growth factors versus platelet rich fibrin both combined with β -tri calcium phosphate and hydroxyapatite bone graft in the treatment of intrabony defects in patients with moderate to severe chronic periodontitis.

The patients who participated in this study were selected according to inclusion and exclusion criteria previously described in the materials and methods section to avoid bizarre selection. The selected patients were randomly classified using sealed envelopes to prevent bias.

Furthermore, patients contributed in the current study were medically free to avoid the possible impact of systemic diseases on the periodontal health condition and their possible effects on the tested clinical parameters since many systemic disorders have been implicated as risk factors for periodontal treatment success.^[19] Smokers were also excluded from the present study as it has been evidenced that smoking is associated with decreased vascular flow and abnormal functioning PMNs that impair wound healing. Occlusal stent was used as a fixed landmark to facilitate sequential post-surgical evaluation, in terms of probing pocket depth (PPD) and clinical attachment level (CAL) to obtain comparable and reliable measurements.^[165]

The rationale for using CGF in the current study was based on its high content of growth factors, higher tensile strength, higher viscosity and higher adhesive strength than other platelet concentrates.^[20, 21] CGF is believed to be of clinical benefit for improving periodontal health as the fibrin network containing such platelets and leukocytes able to provide a sort of scaffold for cells migration as fibroblasts and endothelial cells involved in angiogenesis, tissue remodeling, cell proliferation and osteogenic differentiation as evidenced in many studies.^[22-24]

PRF was selected in this study as it consists of a polymerized fibrin matrix with the incorporation of platelets, leukocyte and cytokines and the presence of circulating stem cells. Its matrix can release various growth factors and cytokines locally at the wound site for a prolonged period of time which play important role in various stages of wound healing promoting periodontal tissue regeneration.^[25-27] Using the combination of HA+ β -TCP bone graft was due to its good biocompatibility, resorbability and osteoconductivity so act as a scaffold for delivering the action of growth factors similarly [28] and recommended in the management of periodontal and peri-implant bone defects cases as well as of bone augmentation procedures.^[7]

Evaluation of clinical results

Upon comparing the mean values of PI and BOP for the two groups there were no statistically significant difference at different follow up periods. These results attributed to the comprehensive oral hygiene instructions followed properly by the patients, periodic maintenance program meticulous scaling for supra and sub gingival plaque and calculus and insequence reduction of inflammation.^[29]

There was high significant reduction in PPD and CAL in both studied groups at all study intervals as compared to baseline. Furthermore, comparison for PPD and CAL showed that at 3 and 6 months study intervals, there was a statistically significant difference in favor of group I.

The explanation for this in group I may be due to the effect of high content of growth factors

in CGF on vascular maintenance, neovascularisation, angiogenesis and tissue regeneration such as TGF- β 1, VEGF and CD-34^[22] in addition CGF enhances cell proliferation in all the three different cell types (fibroblasts, endothelial cells and osteoblasts) involved in angiogenesis, tissue remodeling and regeneration,^[30, 31] which protect the growth factors from proteolysis and prolongs its duration of action and enhances cell proliferation and osteogenic differentiation as documented by Borsani et al.^[30]

The results of group II may be due to the composition of PRF which are platelets, growth factors, cytokines and slowly degrading fibrin matrix^[32-34] which may play a significant role in the self-regulation of inflammatory phenomena within grafted material.^[35]

Our results were supported by Masuki et al.,^[24] who demonstrated that CGF preparation contain significant amounts of growth factors and cytokines capable of stimulating cell proliferation, angiogenesis, tissue remodeling, better soft tissue healing, suggesting CGF function not only as a scaffolding material but also as a reservoir to deliver certain growth factors at the site of application. These results were consistent with Qiao et al.,^[36] who compared CGFs + bovine porous bone mineral (BPBM) versus BPBM alone. Their results indicated that the CGFs + BPBM combination improved clinical parameter (CAL, PPD) better than BPBM alone in the treatment of human intrabony defects.

Evaluation of radiographic results:

In the current study, radiographic evaluation by CBCT which considered the non-invasive, superior technique for assessing hard tissue changes, bone gain, bone density and visualize tooth and its surrounding structure. So in the present study CBCT was used for radiographic evaluation of bone level parameters as vertical depth of defect (VD), alveolar crest height (ACH), width of defect (WD), area of defect (AD) and bone density (BD).^[15, 37-39]

At baseline, statistical analysis of data revealed no significant differences between the measured radiographic parameters. Accordingly, any difference during the study period between the two groups would be due to the type of graft material used. Comparing the two groups at 6 months study interval, results showed that, there was statistically significant difference in terms of VD in favor of group I and also better improvement but not statistically significant in bone density values comparing to group II, while there was no significant difference between both groups in terms of ACH, WD and AD.

The possible explanation for these favorable radiographic results of CGF treated group which showed better and rapid increase in bone formation and bone mineral density may be due to the effect of CGF when mixed with bone graft material that gave sticky bone graft enriched with growth factors that didn't migrate upon shaking during healing period.^[21] also the higher content of CGF with growth factors that have been shown to be expressed on most cell types such as fibroblasts, osteoblasts, endothelial cells and macrophages thus affecting bone metabolism through modulation of both osteoclastic and osteoblastic cell differentiation and activity that play a major role in bone regeneration.^[24, 40-44]

While the radiographic results in group II may be attributed to PRF ability to enhance osteogenic lineage differentiation of alveolar bone progenitors more than of periodontal progenitors by augmenting osteoblast differentiation and mineralized nodule formation via its principal component fibrin.^[45]

Furthermore, results of group I were confirmed by multiple studies utilized autologous concentrated growth factors (CGF) enriched bone graft matrix (sticky bone) in ridge augmentation prior to and at the time of implant placement. Six and twelve months histological and radiographic evaluation showed favorable new bone formation without the need for rigid membranes because sticky bone didn't migrate during healing period.^[40, 46] and park et al.,^[47] in their vitro study compared the new bone formation using an autologous CGF graft alone and PRF graft alone in adults dogs. Results showed that CGF showed better new bone formation rate in peri-implant bone defects.

While in another study by Kim et al.,^[48] compared the effect of PRP, PRF and CGF on bone healing in rabbit skull, they found that the effect of PRP, PRF and CGF was similar and may be useful to increase the success rate of bone grafting.

Conclusion

Based on the results of the present study, both treatment modalities resulted in clinical improvement as well as radiographic evidence of bone regeneration so these materials could be used successfully in the treatment of patients suffering from chronic periodontitis and intra-bony defects and Since the preparation of CGF and PRF nearly the same and the addition of CGF to bone graft gave better clinical and radiographical outcomes, if the periodontist would choose between the two materials, they would logically select CGF.

References

1. Elamrousy W. Effect of locally delivered 0.2% Thymoquinone gel in subjects with Grade C Periodontitis: Clinical, Immunological and Microbiological Assessment. *European Journal of Molecular & Clinical Medicine*, 2021; 5(1): 89-101. doi: 10.31838/ejmcm.05.01.11.
2. Slotte C, Asklöv B, Sultan J, Norderyd O. A Randomized Study of Open-Flap Surgery of 32 Intrabony Defects With and Without Adjunct Bovine Bone Mineral Treatment. *Journal of periodontology*. 2012;83:999-1007.

3. Elamrousy W, Nassar M, ragheb A, Alnomany F, Marzok M. radiographic bone changes around immediately placed immediately restored dental implants in periodontally compromised sites. *Dentistry* 2013; 3: 161.
4. Rastogi P, Saini H, Singhal R, Dixit J. Periodontal regeneration in deep intrabony periodontal defect using hydroxyapatite particles with platelet rich fibrin membrane—a case report. *Journal of oral biology and craniofacial research.* 2011;1:41-3.
5. Bauer TW, Muschler GF. Bone graft materials: an overview of the basic science. *Clinical Orthopaedics and Related Research*®. 2000;371:10-27.
6. Shue L, Yufeng Z, Mony U. Biomaterials for periodontal regeneration: a review of ceramics and polymers. *Biomatter.* 2012;2:271-7.
7. Nery EB, LeGeros RZ, Lynch KL, Lee K. Tissue response to biphasic calcium phosphate ceramic with different ratios of HA/ β TCP in periodontal osseous defects. *Journal of periodontology.* 1992;63:729-35.
8. Nevins M, Camelo M, Nevins ML, Schenk RK, Lynch SE. Periodontal regeneration in humans using recombinant human platelet-derived growth factor-BB (rhPDGF-BB) and allogenic bone. *Journal of periodontology.* 2003;74:1282-92.
9. Choukroun J, Adda F, Schoeffler C, Vervelle A. Une opportunité en paro-implantologie: le PRF. *Implantodontie.* 2001;42:e62.
10. Sohn D, Moon J, Moon Y, Park J, Jung H. The use of concentrated growth factors (CGF) for sinus augmentation. *J Oral Implant.* 2009;38:25-38.
11. Lucarelli E, Beccheroni A, Donati D, Sangiorgi L, Cenacchi A, Del Vento AM, et al. Platelet-derived growth factors enhance proliferation of human stromal stem cells. *Biomaterials.* 2003;24:3095-100.
12. Sacco L. Lecture, International academy of implant prosthesis and osteoconnection. *Lecture.* 2006;12:4.
13. Clark R. Fibrin and wound repair. *Ann NY Acad Sci.* 2001;936:355-67.
14. Armitage GC. Classifying periodontal diseases—a long-standing dilemma. *Periodontology* 2000. 2002;30:9-23.
15. Misch KA, Yi ES, Sarment DP. Accuracy of cone beam computed tomography for periodontal defect measurements. *Journal of periodontology.* 2006;77:1261-6.
16. Silness J, Løe H. Periodontal disease in pregnancy II. Correlation between oral hygiene and periodontal condition. *Acta odontologica scandinavica.* 1964;22:121-35.
17. Ainamo J, Bay I. Problems and proposals for recording gingivitis and plaque. *International dental journal.* 1975;25:229-35.
18. Ramfjord SP. The periodontal disease index (PDI). *The Journal of Periodontology.* 1967;38:602-10.
19. Page RC. The pathobiology of periodontal diseases may affect systemic diseases: inversion of a paradigm. *Annals of periodontology.* 1998;3:108-20.
20. Sohn D-S. The effect of concentrated growth factors on ridge augmentation. *Dental Inc.* 2009:34-40.
21. Sohn D-S, Huang B, Kim J, Park WE, Park CC. Utilization of autologous concentrated growth factors (CGF) enriched bone graft matrix (Sticky bone) and CGF-enriched fibrin membrane in Implant Dentistry. *Jr Implant Adv Cli Dent.* 2015;7:11-29.
22. Rodella LF, Favero G, Boninsegna R, Buffoli B, Labanca M, Scari G, et al. Growth factors, CD34 positive cells, and fibrin network analysis in concentrated growth factors fraction. *Microscopy research and technique.* 2011;74:772-7.
23. Yu B, Wang Z. Effect of concentrated growth factors on beagle periodontal ligament stem cells in vitro. *Molecular medicine reports.* 2014;9:235-42.
24. Masuki H, Okudera T, Watanebe T, Suzuki M, Nishiyama K, Okudera H, et al. Growth factor and pro-inflammatory cytokine contents in platelet-rich plasma (PRP), plasma rich in growth factors (PRGF), advanced platelet-rich fibrin (A-PRF), and concentrated growth factors (CGF). *International journal of implant dentistry.* 2016;2:19.
25. Agrawal M, Agrawal V. Platelet rich fibrin and its applications in dentistry-A review article. *National Journal of Medical and Dental Research.* 2014;2:51.

26. Choukroun J, Diss A, Simonpieri A, Girard M-O, Schoeffler C, Dohan SL, et al. Platelet-rich fibrin (PRF): a second-generation platelet concentrate. Part IV: clinical effects on tissue healing. *Oral Surgery, Oral Medicine, Oral Pathology, Oral Radiology, and Endodontology*. 2006;101:e56-e60.
27. Dohan Ehrenfest DM, Del Corso M, Diss A, Mouhyi J, Charrier J-B. Three-dimensional architecture and cell composition of a Choukroun's platelet-rich fibrin clot and membrane. *Journal of periodontology*. 2010;81:546-55.
28. Çalışır M, Akpınar A, Alpan A. Platelet-Rich Fibrin Membrane Combined With Biphasic Calcium Phosphate Bone Graft in the Treatment of Intrabony Defect: A Three-Year Case Report. *International Journal of Oral and Maxillofacial Pathology*. 2014;5:21-5.
29. Matthews DC. Prevention and treatment of periodontal diseases in primary care. *Evidence-based dentistry*. 2014;15:68-9.
30. Borsani E, Bonazza V, Buffoli B, Cocchi MA, Castrezzati S, Scari G, et al. Biological characterization and in vitro effects of human concentrated growth factor preparation: An innovative approach to tissue regeneration. *Biology and Medicine*. 2015;7:726.
31. Qiao J, An N. Effect of concentrated growth factors on function and Wnt3a expression of human periodontal ligament cells in vitro. *Platelets*. 2017;28:281-6.
32. Dohan DM, Choukroun J, Diss A, Dohan SL, Dohan AJ, Mouhyi J, et al. Platelet-rich fibrin (PRF): a second-generation platelet concentrate. Part I: technological concepts and evolution. *Oral Surgery, Oral Medicine, Oral Pathology, Oral Radiology, and Endodontology*. 2006;101:e37-e44.
33. Dohan DM, Choukroun J, Diss A, Dohan SL, Dohan AJ, Mouhyi J, et al. Platelet-rich fibrin (PRF): a second-generation platelet concentrate. Part II: platelet-related biologic features. *Oral Surgery, Oral Medicine, Oral Pathology, Oral Radiology, and Endodontology*. 2006;101:e45-e50.
34. Toffler M, Toscano N, Holtzclaw D, Corso MD, Ehrenfest DD. Introducing Choukroun's platelet rich fibrin (PRF) to the reconstructive surgery milieu. *J Implant Adv Clin Dent*. 2009;1:21-30.
35. Dohan DM, Choukroun J, Diss A, Dohan SL, Dohan AJ, Mouhyi J, et al. Platelet-rich fibrin (PRF): a second-generation platelet concentrate. Part III: leucocyte activation: a new feature for platelet concentrates? *Oral Surgery, Oral Medicine, Oral Pathology, Oral Radiology, and Endodontology*. 2006;101:e51-e5.
36. Qiao J, Duan J, Zhang Y, Chu Y, Sun C. The effect of concentrated growth factors in the treatment of periodontal intrabony defects. *Future science OA*. 2016;2.
37. Takeshita WM, Iwaki LCV, Da Silva MC, Tonin RH. Evaluation of diagnostic accuracy of conventional and digital periapical radiography, panoramic radiography, and cone-beam computed tomography in the assessment of alveolar bone loss. *Contemporary clinical dentistry*. 2014;5:318.
38. Mengel R, Kruse B, Flores-de-Jacoby L. Digital volume tomography in the diagnosis of peri-implant defects: an in vitro study on native pig mandibles. *Journal of periodontology*. 2006;77:1234-41.
39. Georgescu CE, Mihai A, Didilescu AC, Moraru R, Nimigean V, Nimigean VR, et al. Cone beam computed tomography as a method of quantitative and qualitative analysis of alveolar crest in the frontal mandibular area. *Rom J Morphol Embryol*. 2010;51:713-7.
40. Sohn D-S, Huang B, Kim J, Park WE, Park CC. Utilization of autologous concentrated growth factors (CGF) enriched bone graft matrix (Sticky bone) and CGF-enriched fibrin membrane in Implant Dentistry. *Jr Implant Adv Cli Dent*. 2015;7:11-29.
41. Chen D, Zhao M, Mundy GR. Bone morphogenetic proteins. *Growth factors*. 2004;22:233-41.
42. Ripamonti U, Heliotis M, Rueger D, Sampath T. Induction of cementogenesis by recombinant human osteogenic protein-1 (hop-1/bmp-7) in the baboon (*Papio ursinus*). *Archives of oral biology*. 1996;41:121-6.
43. Tatakis DN, Wikesjö UM, Razi SS, Sigurdsson TJ, Lee MB, Nguyen T, et al. Periodontal repair in dogs: effect of transforming growth factor- β 1 on alveolar bone and cementum regeneration. *Journal of clinical periodontology*. 2000;27:698-704.
44. Howell TH, Fiorellini JP, Paquette DW, Offenbacher S, Giannobile WV, Lynch SE. A phase I/II clinical trial to evaluate a combination of recombinant human platelet-derived growth factor-BB and recombinant human insulin-like growth factor-I in patients with periodontal disease. *Journal of periodontology*. 1997;68:1186-93.
45. Li Q, Pan S, Dangaria SJ, Gopinathan G, Kolokythas A, Chu S, et al. Platelet-rich fibrin promotes periodontal regeneration and enhances alveolar bone augmentation. *BioMed research international*. 2013;2013:13.

46. Gheno E, Palermo A, Rodella LF, Buffoli B. The effectiveness of the use of xenogeneic bone blocks mixed with autologous Concentrated Growth Factors (CGF) in bone regeneration techniques: a case series. *Journal of Osseointegration*. 2014;6:37-42.
47. Park H-C, Kim S-G, Oh J-S, You J-S, Kim J-S, Lim S-C, et al. Early bone formation at a femur defect using CGF and PRF grafts in adult dogs: a comparative study. *Implant dentistry*. 2016;25:387-93.
48. Kim T-H, Kim S-H, Sándor GK, Kim Y-D. Comparison of platelet-rich plasma (PRP), platelet-rich fibrin (PRF), and concentrated growth factor (CGF) in rabbit-skull defect healing. *Archives of oral biology*. 2014;59:550-8.