

Volume 7 Issue 7,  
August 2021

## Copyright

©2021 Fernando Duarte. This is an open access article distributed under the terms of the Creative Commons Attribution License, which permits unrestricted use, distribution, and reproduction in any medium, provided the original author and source are credited



## Citation

Fernando Duarte (2021). Correlation between MRI and Biomodelling Analysis in Masseter Muscle Following Orthognathic Surgery *Int J Dent & Ora Hea*. 7:7.

ISSN 2471-657X

Published by  
Biocore Group |  
[www.biocoreopen.org/ijdo/archive.php](http://www.biocoreopen.org/ijdo/archive.php)

## Research Article

### Correlation between MRI and Biomodelling Analysis in Masseter Muscle Following Orthognathic Surgery

Fernando Duarte<sup>1</sup>, João Neves Silva<sup>2</sup>, Carina Ramos<sup>2</sup>, Colin Hopper<sup>2</sup>

<sup>1</sup> *Clitrofa – Centro Médico, Dentário e Cirúrgico, Avenida de Paradela, Trofa – Portugal.*

<sup>2</sup> *Instituto Superior de Saúde – Portugal.*

<sup>3</sup> *Oral Oncology at Instituto de Ciências Biomédicas Abel Salazar – Oporto University – Portugal.*

<sup>4</sup> *Oral and Maxillofacial Surgery Department at Eastman Dental Institute – University College of London. UK.*

**Corresponding author:** Fernando Duarte

Clitrofa - Centro Médico, Dentário e Cirúrgico, Clitrofa - Centro Médico, Dentário e Cirúrgico, Avenida de Paradela Trofa - Portugal.

E-mail: [fduarte@clitrofa.com](mailto:fduarte@clitrofa.com)

**Article History:** Received: August 09, 2021;  
Accepted: August 15, 2021;  
Published: August 20, 2021.

## Abstract

**Purpose:** This pilot investigation was designed to apply several and innovative methods of measuring muscle area, volume, structure, function and fibre orientation to a situation where adaptation of muscle is pivotal to the success of a therapeutic approach.

**Materials and Methods:** Patients attending the combined orthodontic/orthognathic surgery clinic at Clitrofa – Centro Médico, Dentário e Cirúrgico, in Trofa - Portugal were screened using a standardized Magnetic Resonance Imaging protocol, with fine overlapping slices of 1 mm thickness and a spacing of 0.8 mm during 7 minutes. The software used was the Anatomics™ that allows the correction of muscle and bone limits.

The landmarks considered for this study were: a) the anterior angle from the long axis of masseter muscle versus angle between lower border of the zygomatic bone and the mastoid process; and b) the anterior angle from the long axis of the masseter muscle versus the mandibular plane. The angles were measured by two different observers. The values were registered (T0) and the procedure was repeated after 1 hour (T1), and 6 to 12 months after surgery (T2).

**Conclusions:** Significant statistical differences ( $p < 0,05$ ) have been identified between Time 2 (1–6 months after surgery) and Times 0 and 1 (prior to surgery) in the mean P2 angle measured, both for Examiner F and C. These differences reveal the masseter muscle adaptation following bimaxillary osteotomy involving a combination of maxillary Le Fort I impaction procedure coupled with a sagittal split advancement of the mandible in this study-case. The measurement of “P1 Masseter Muscle/Zygomatic Bone/Process Mastoid Anterior Angle” and “P2 Masseter Muscle/Mandibular Angle” can therefore be a valuable tool for controlling the reworking of masseter muscle upon orthognathic surgery.

## Keywords

Orthognathic Surgery; Masseter Muscle; MRI Analysis; Biomodelling Analysis

## Declaration of Conflicting Interest

The author[s] declared no potential conflicts of interest with respect to the research, authorship, and/or publication of this article.

## INTRODUCTION

Advances in medical imaging have created ever increasing volumes of complex data obtained from the patient. The interpretation of such information has become a specialty in itself and the surgeon at times may be left bewildered as to how best to apply the available information to the practicalities of physical intervention. The surgeon seeks to understand the exact morphology of the abnormality, its

relationships to surrounding anatomy and the best way to access and correct the pathology operatively. Such specific information is not readily available in the radiologist's report and however experienced the surgeon may be at interpreting images such questions, often cannot be easily answered<sup>1</sup>.

Three-dimensional (3-D) imaging has been developed to narrow the communication gap between radiologist and surgeon. By using 3-D, imaging a vast number of complex slice images can be quickly appreciated. The term "three-dimensional" however, is not a truly accurate description of these images as they are still displayed on a radiological film or flat screen in only two dimensions<sup>1</sup>.

For harmonious vertical facial growth and development to exist, the growth on the front of the face must be the same as on the back. If this does not occur, there may be a relative growth rotation of the mandible. For example, if the growth in the posterior part of the face exceeds what occurred previously, the net effect will be an anterior rotation of the mandible, producing the typical deformity of the short face and the deep overbite associated with the short face syndrome<sup>2</sup>. At the opposite end, where growth at the back of the face can be severely reduced compared to what occurred earlier, a clockwise opening or rotation of the jaw is evident, with the net effect of being an excessive anterior facial height and often a bitten anterior opening, associated with a deformity of the long face<sup>3</sup>.

For generations, both clinicians and scientists have argued as to the respective contribution of genetics and, so called, environmental factors in influencing ultimate facial form and associated malocclusion. Of all the possible environmental influences, it is not surprising that bearing in mind the origins and insertions of the muscles of mastication, and in particular the masseter and medial pterygoid muscle, that the question has arisen as to whether, or not, abnormalities in the structure and function of the muscular pterygo-masseteric sling could, in any way, influence vertical development in the posterior part of the face. Furthermore, if treatment interventions necessitate a change in function of the muscles that support the mandible, do the adaptive capability of these muscles in any way influence the stability of the treatment outcome<sup>4</sup>.

## **MRI AND BIO-MODELLING**

Computers are used increasingly as a supportive tool for the diagnosis, operation planning, and treatment in medicine and dentistry. They are used in connection with the modern digital imaging techniques such as computer tomography and magnetic resonance imaging, as well as ultrasound to improve the visualization of anatomical and physiological conditions in keeping with the human imagination<sup>5</sup>.

The ability to extract accurate three-dimensional (3D) images from magnetic resonance imaging (MRI), has proven to be a very useful diagnostic tool to extract the muscle from the scan with secure margins identification and also to extract the facial bones with considerable detail<sup>6</sup>.

The reconstruction of muscles and bone from the same scan have allowed visualisation of the muscle fibre orientation in relation to the muscle's bony attachments. This could enabled the measurement of potential changes in orientation in relation to a static landmark unaffected by surgery (eg. Frankfort plane) or in relation to functional identifiers (eg. Occlusal plane).

## **MUSCLES ROLE**

Many forms of interceptive treatment, whether they be purely orthodontic in nature or in combination with surgery, bring about changes in the muscles of mastication with regard to one or more of the following changes: a) in muscle fibre orientation; b) changes in the functioning length of fibres; c) changes in muscle structure; and d) changes in muscle phenotype. Successful treatment requires both reorganisation in the connective tissue and regeneration of muscle fibres. Reorganisation of connective tissue is an extremely complex process involving muscle derived stem cells (satellite cells), extra-cellular matrix molecules and receptors for the extra-cellular matrix (for example integrins). Remodeling of the extra-cellular matrix is mediated by a family of enzymes known as matrix metalloproteinases (MMPs)<sup>7,8</sup>. MMP2 is expressed during the regeneration of new myofibres and is a known mechano-responsive gene. A knowledge of how muscles respond to clinical interventions is pivotal to treatment success and can influence the way in which a particular treatment modality is applied<sup>7,8</sup>.

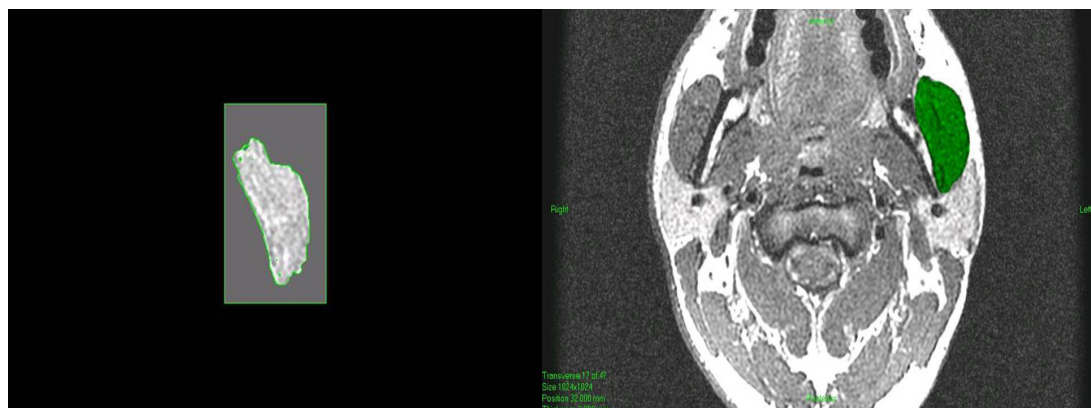
With regard to orthognathic surgery the golden rule is that surgery must not stretch the pterygo-masseteric sling, otherwise relapse is likely to occur. This is predominantly through the speed of insult to the muscle in relation to the timing of the muscle adaptive process. The consequence is either an immediate reversion back to the original functioning length of the muscle and return of the bony fragments back to their original pre-surgical position, and/or migration of the muscle attachment along the surface of the bone, thereby leading to an area of bone denuded of muscle force, which ultimately leads to resorption of the bony muscular processes.

One way in which this can be studied more closely is through refinements in protocols for 3-D MRI of the face and jaws. Increasing the resolution of the tomographic cuts has led to a resolution which facilitates the identification of not only the origins and insertions of the muscles of mastication but

even the orientation of individual muscle fibre bundles. It is therefore possible to study the changes in muscle fibre orientation in relation to landmarks such as the functional occlusal plane and also those landmarks unaffected by surgery, for example the cranial base.

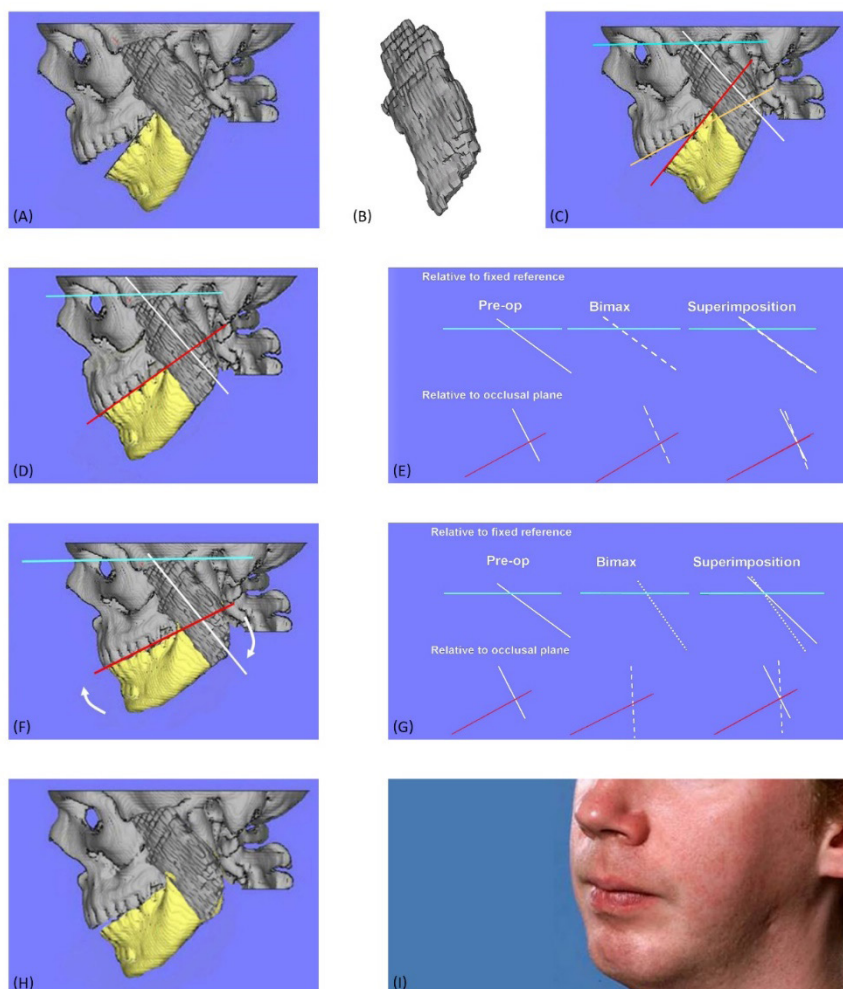
## MATERIALS AND METHODS

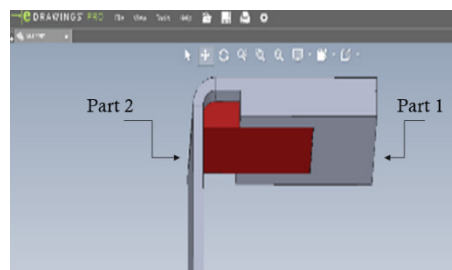
Ten patients attending the combined orthodontic/orthognathic surgery clinic at the Clitrofa – Centro Médico, Dentário e Cirúrgico, in Trofa - Portugal were tested according to the following protocol: Accurate extraction of muscles and facial bones using the same scan from MRI three-dimensional (3D), using a standardize scanning process, with fine overlapping slices of 1 mm thickness and a spacing of 0.8 mm during 7 minutes<sup>6</sup>. The software used was the Anatomicst<sup>TM</sup> that allows the correction of muscle and bone limits at any time<sup>6</sup>.



**Figure 1** Identification of masseter muscle limits in a sagittal plane

The landmarks considered for this study were: (a) the anterior angle from the long axis of masseter muscle versus angle between lower border of the zygomatic bone and the mastoid process, (b) the anterior angle from the long axis of the masseter muscle versus the mandibular plane<sup>9</sup>.






**Figure-1** The design of the st.st mold and guiding part of the preparation

#### 4.3. Effect of combination between two variables on blending

By combination of the two variables, the BvM had the least color difference ( $\Delta E = 3.36$ ) which is within the clinically acceptance range and this is confirmed by the highest percentage of the visual scoring which was (28%), this could be as mentioned before, bevel allows for a gradual transition and provides bulk across the cavosurface angle (J.Bagheri and G.E.Denehy,2015; Y.K.Lee,2005) , and microhybrid has low translucency than nanofill as nanofill composite has filler particle size range from 0.005 to 0.01 $\mu$ m




**Figure-2** Skirt preparation through the guide



**Figure-3** Depth of the skirt 1mm



**Figure-4** Bevel preparation through the guide



**Figure-5** 2mm bevel length with depth 1mm, leaving 1mm unprepared from the thickness of the block.



while microhybrid has the smallest particle size is  $0.04\mu\text{m}$  and the organic fillers in the nanofill has high transparency, and as we said before the microhybrid resin composite may have BE more than the nanofill resin composite due to microhybrid composite has higher filler weight 86% than the nanofill 78% [I.L.Vegting, et al.,2011; B.J.Kim and Y.K.Lee,2009; B.H.Cho, et al.,2007], not only this but also the color A2 from the VITA classic color scale and may appear a little darker and shows low translucency values [D.Awad, et al.,2015] So by combination microhybrid resin composite with bevel preparation on VITA enamic, this permits blending of color and gives more color depth at the repair site. The rest groups had color difference above the acceptable range statistically ( $\Delta E=3.7$ ). Values of  $\Delta E$  might have been smaller if the diameter of the circle reflecting the light in the spectrophotometer was smaller which might have affected the chameleon effect and hence blending of the color and color match [34] [Alghazali N., et al.,2011]. With the aforementioned results, it is clear that color blending at repair site is a multifactorial process depending on type of substrate material, design of preparation as well as the type of repairing composites; and the null hypothesis for the study was rejected. Further studies are highly needed to have an accurate recommendation of the ideal repair material and design for such ceramic material.

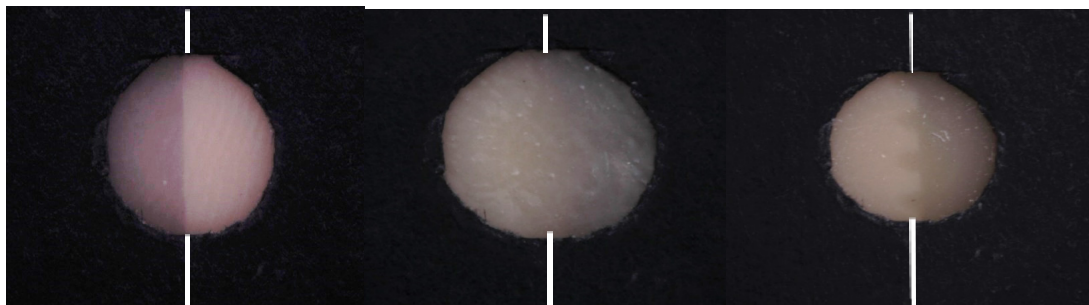
## 5. Conclusion

**Within the limitation of this study, it could be concluded that:**

Preparation designs and composite material type (microhybrid and nanofill) had an effect on the color match and blending effect. Combining the bevel preparation with microhybrid composite provided the best color matching instrumentally as well as visual color blending.

## References

- [1] A. Coldea, M. V. Swain, and N. Thiel, "Mechanical properties of polymer-infiltrated-ceramic-network materials," *Dent. Mater.*, vol. 29, no. 4, pp. 419–426, 2013. <https://doi.org/10.4317/jced.52521>
- [2] A. Della, P. H. Corazza, and Y. Zhang, "Characterization of a polymer-infiltrated ceramic-network material," *Dent. Mater.*, vol. 30, no. 5, pp. 564–569, 2014. <https://doi.org/10.1016/j.dental.2014.02.019>
- [3] A. Furtado de Mendonca, M. Shahmoradi, C. V. D. de Gouvêa, G. M. De Souza, and A. Ellakwa, "Microstructural and Mechanical Characterization of CAD/CAM Materials for Monolithic Dental Restorations," *J. Prosthodont.*, pp. 3–10, 2018. <https://doi.org/10.1111/jopr.12964>
- [4] Alghazali N, Burnside G, Smith PW, Preston AJ, and Jarad FD. "Performance Assessment of Vita Easy Shade Spectrophotometer on Colour Measurement of Aesthetic Dental Materials," no. December 2011; 19(4):168. [https://doi.org/10.1922/EJPRD\\_1003Jarad07](https://doi.org/10.1922/EJPRD_1003Jarad07)
- [5] B. J. Kim and Y. K. Lee, "Influence of the shade designation on the color difference between the same shade-designated resin composites by the brand," *Dent. Mater.*, vol. 25, no. 9, pp. 1148–1154, 2009. <https://doi.org/10.1016/j.dental.2009.04.001>
- [6] B. Loomans and M. Özcan, "Intraoral Repair of Direct and Indirect Restorations: Procedures and Guidelines," *Oper. Dent.*, vol. 41, no. 7, pp. 68–78, 2016. <https://doi.org/10.14295/bds.2020.v23i3.2005>
- [7] Bonfante E, Thompson V, Gracis S, Ferencz J, and Silva N. "A New Classification System for All-Ceramic and Ceramic-like Restorative Materials," *Int. J. Prosthodont.*, 2016; 28(3): 227–235. <https://doi.org/10.11607/ijp.4244>
- [8] Cho, Byeong-Hoon, Yong-Kyu Lim, and Yong-Keun Lee. "Comparison of the color of natural teeth measured by a colorimeter and Shade Vision System." *dental materials* 23, no. 10 (2007): 1307–1312. <https://doi.org/10.1016/j.dental.2006.11.008>
- [9] D. Awad, B. Stawarczyk, A. Liebermann, and N. Ilie, "Translucency of esthetic dental restorative CAD/CAM materials and composite resins with respect to thickness and surface roughness," *J. Prosthet. Dent.*, vol. 113, no. 6, pp. 534–540, 2015. <https://doi.org/10.1016/j.prosdent.2014.12.003>



**Figure-6** The center of the paper coincides with the center of the prepared part of the specimen.

Composite	Preparation extension (mean±SD)			p-value
	Butt joint	2 mm bevel	Skirt	
Nano-filled	5.25±0.09B	6.01±0.12A	5.77±0.17B	<0.001*
Micro-hybrid	6.41±0.15A	3.36±0.13B	6.74±0.06A	<0.001*
p-value	<0.001*	<0.001*	<0.001*	

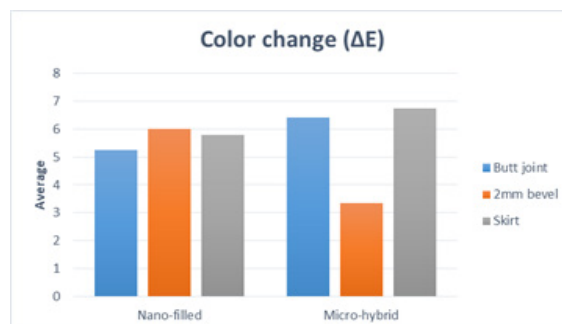
**Table-3** Mean  $\pm$  standard deviation (SD) of color difference ( $\Delta E$ ) for different composite types and preparation extension designs.

*Different superscript letters indicate a statistically significant difference within the same horizontal row\*; significant ( $p \leq 0.05$ ) ns; non-significant ( $p > 0.05$ )*

[10] D'Antonio, Tracy A. "Esthetic blending: visual vs. spectrophotometric data analysis for different bevels in class IV dental composite direct restorations." (2017). <https://doi.org/10.17077/etd.7kqlugs0>

[11] D'Antonio, Tracy A. "Esthetic blending: visual vs. spectrophotometric data analysis for different bevels in class IV dental composite direct restorations." (2017) <https://doi.org/10.17077/etd.7kqlugs0>

[12] Duzyol M, Sagsoz O, Polat Sagsoz N, Akgul N, and Yildiz M. "The Effect of Surface Treatments on the Bond

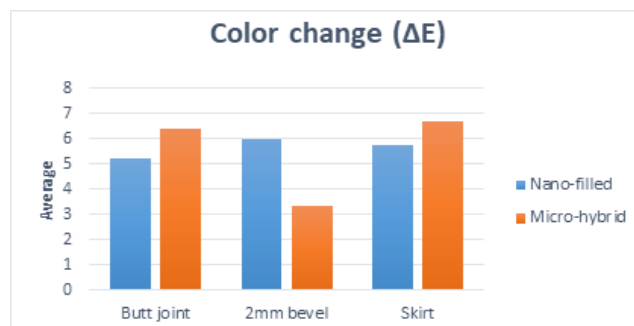


**Figure-7** Bar chart showing average color difference ( $\Delta E$ ) for different composite types and preparation extension designs (A)

Strength Between CAD/CAM Blocks and Composite Resin," J. Prosthodont., Vol.25(6), pp. 466–471, 2016. <https://doi.org/10.1111/jopr.12322>

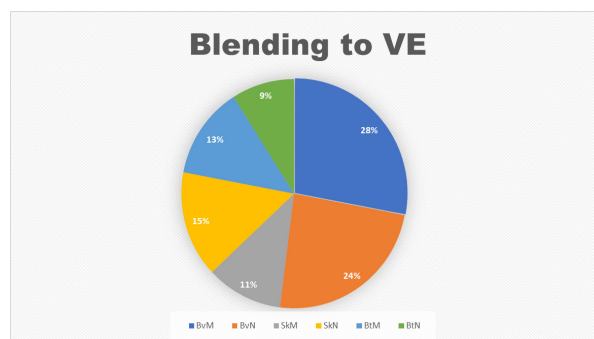
[13] Eid, Hani, and George White. "Class IV preparations for fractured anterior teeth restored with composite resin restorations." Journal of Clinical Pediatric Dentistry 27, no. 3 (2003): 201-211. <https://doi.org/10.17796/jcpd.27.3.c3249414730lw154>

[14] J. B. Black and D. Dm, "Class IV composite resin restorations," J. Am. Dent. Assoc., vol. 103, no. 1, pp. 42–46, 2011. <https://doi.org/10.14219/jada.archive.1981.0442>



**Figure-8** Bar chart showing average color difference ( $\Delta E$ ) for different composite types and preparation extension designs (B)

[15] J. Bagheri and G. E. Denehy, "Effect of Enamel Bevel and Restoration Lengths on Class IV Acid-Etch Retained Composite Resin Restoration," *J. Am. Dent. Assoc.*, vol. 107, no. 6, pp. 951–953, 2015. <https://doi.org/10.14219/jada.archive.1983.0376>



**Figure-9** Pie Chart of the visual scoring for exact match

[16] J. Bagheri and G. E. Denehy, "Effect of Enamel Bevel and Restoration Lengths on Class IV Acid-Etch Retained Composite Resin Restoration," *J. Am. Dent. Assoc.*, vol. 107, no. 6, pp. 951–953, 2015. <https://doi.org/10.14219/jada.archive.1983.0376>

[17] J. Bagheri and G. E. Denehy, "Effect of Enamel Bevel and Restoration Lengths on Class IV Acid-Etch Retained Composite Resin Restoration," *J. Am. Dent. Assoc.*, vol. 107, no. 6, pp. 951–953, 2015. <https://doi.org/10.14219/jada.archive.1983.0376>

[18] Low, T., and Z. A. Majid. "The direct use of composite materials in the restoration of fractured incisors." *Journal of dentistry* 7, no. 1 (1979): 57-63 [https://doi.org/10.1016/0300-5712\(79\)90040-X](https://doi.org/10.1016/0300-5712(79)90040-X)

[19] M. Tsubone, M. Nakajima, K. Hosaka, R. M. Foxton, and J. Tagami, "Color shifting at the border of resin composite restorations in human tooth cavity," *Dent. Mater.*, 2012. <https://doi.org/10.1016/j.dental.2012.04.032>

[20] Malhotra, Neeraj, and Shashi Rashmi Acharya. "Conservative approach for esthetic repair of fractured ceramic facing in ceramic-fused-to-metal crowns: a case series." *Compendium of continuing education in dentistry* (Jamesburg, NJ: 1995) 33, no. 10 (2012): E123-9.

[21] Mirmohammadi, Hesam. "Resin-based ceramic matrix composite materials in dentistry." In *Advances in Ceramic Matrix Composites*, pp. 741-762. Woodhead Publishing, 2018. <https://doi.org/10.1533/9780857098825.3.656>

[22] Paul, S., A. Peter, N. Pietrobon, and C. H. F. Hämmerle. "Visual and spectrophotometric shade analysis of human teeth." *Journal of dental research* 81, no. 8 (2002): 578-582. <https://doi.org/10.1177/154405910208100815>

[23] R. D. Paravina, S. Westland, F. H. Imai, M. Kimura, and J. M. Powers, "Evaluation of blending effect of composites related to restoration size," *Dent. Mater.*, vol. 22, no. 4, pp. 299–307, 2006. <https://doi.org/10.1016/j.dental.2005.04.022>

[24] R. M. Abdelraouf and N. A. Habib, "Color-Matching and Blending-Effect of Universal Shade Bulk-Fill-Resin-Composite in Resin-Composite-Models and Natural Teeth," *Biomed Res. Int.*, vol. 2016. <https://doi.org/10.1155/2016/4183432>

[25] Ribeiro, Rodrigo Alves, Darlene Cristina Ramos Eloy Dantas, Ana Isabella Arruda Meira Ribeiro, Rodivan Braz, Jackson Santos Lobo, Bárbara Vanessa de Brito Monteiro, and Alessandro Leite Cavalcanti. "AvAliAção in vitro da Microinfiltração MArginAl eM restAurAções clAssé ii utilizAndo diferentes técnicAs de inserção de resinA coMpostA." *Revista da Faculdade de Odontologia de Lins* 22, no. 1 (2012): 17-23. <https://doi.org/10.15600/2238-1236/fol.v22n1p17-23>

[26] S. J. Chu, R. D. Trushkowsky, and R. D. Paravina, "Dental color matching instruments and systems. Review of clinical and research aspects," in *Journal of Dentistry*, 2010. <https://doi.org/10.1016/j.jdent.2010.07.001>

[27] S. S. Mikhail, S. R. Schricker, S. S. Azer, W. A. Brantley, and W. M. Johnston, "Optical characteristics of contemporary dental composite resin materials," *J. Dent.*, vol. 41, no. 9, pp. 771–778, 2013. <https://doi.org/10.1016/j.jdent.2013.07.001>

[28] Suh YR, Ahn JS, Ju SW, and Kim KM. "Influences of filler content and size on the color adjustment potential of nonlayered resin composites," *Dent. Mater. J.*, 2016; 36(1): 35–40. <https://doi.org/10.4012/dmj.2016-083>

[29] V. Zahnfabrik, "VITAENAMIC Product Information," vol. 1, pp. 9 2015. <https://doi.org/10.21306/jids.2015.1.02>

[30] van Dijken, Jan WV, and Ulla Pallesen. "Fracture frequency and longevity of fractured resin composite,

polyacid-modified resin composite, and resin-modified glass ionomer cement class IV restorations: an up to 14 years of follow-up." *Clinical Oral Investigations* 14, no. 2 (2010): 217-222. H. <https://doi.org/10.1007/s00784-009-0287-z>

[31] VITA ENAMIC AG, "VITA ENAMIC- Scientific Documentation," no. 08, 2016. <https://doi.org/10.1016/j.jmbbm.2018.08.029>

[32] Y. K. Lee, "Changes in the translucency of porcelain and repairing resin composite by the illumination," *Dent. Mater.*, vol. 23, no. 4, pp. 492–497, 2007. <https://doi.org/10.1016/j.dental.2006.03.004>

[33] Y. K. Lee, "Comparison of CIELAB  $\Delta E^*$  and CIEDE2000 color-differences after polymerization and thermocycling of resin composites," *Dent. Mater.*, vol. 21, no. 7, pp. 678–682, 2005. <https://doi.org/10.1016/j.dental.2004.09.005>





