



Case Report

ISSN 2471-657X

Gingival Overgrowth and Altered Passive Eruption in Adolescents: Literature Review and Case Report

Zanin SB¹, Gisele Fernandes Dias^{*2}, Goiris FAJ³

¹Student in the Dentistry Course at the Campos Gerais Study Center, Ponta Grossa, Parana, Brazil

²Professor of Pediatric Dentistry at the State University of Ponta Grossa, Parana, Brazil

³Professor of Periodontology at the State University of Ponta Grossa and Campos Gerais Study Center, Ponta Grossa, Parana, Brazil

Abstract

Gingival alterations might appear simultaneously as gingival overgrowth and as Altered Passive Eruption - APE. Both can interfere in the patient's smile aesthetics and hamper tooth eruption. However, the prognosis is predictable and the treatment is surgical. Obtaining good aesthetic results and making tooth eruption easier were two objectives achieved in this work. Gingivectomy using special knives, according to Kirkland and Orban is a very successful and predictable surgical procedure

Keywords: Gingival overgrowth, Altered Passive Eruption, Gummy smile, Gingivectomy

Corresponding author: Gisele Fernandes Dias

Professor of Pediatric Dentistry at the State University of Ponta Grossa, Parana, Brazil. E-mail: giodonto@hotmail.com

Citation: Gisele Fernandes Dias et al. (2019), Gingival Overgrowth and Altered Passive Eruption in Adolescents: Literature Review and Case Report. Int J Dent & Oral Heal. 5:1, 09-12

Copyright: ©2019 Gisele Fernandes Dias et al. This is an openaccess article distributed under the terms of the Creative Commons Attribution License, which permits unrestricted use, distribution, and reproduction in any medium, provided the original author and source are credited

Received: October 22, 2018

Accepted: November 02, 2018

Published: January 04, 2019

Introduction

Gingival overgrowth or gingival enlargement is a common characteristic of gingival diseases and its most common form is the chronic inflammatory gingival overgrowth^[1]. It is exclusively induced by bacterial plaque and its main cause is accumulation and retention of bacteria^[2]. In this clinical case, a chronic inflammatory gingival overgrowth and an altered passive eruption – APE^[3] were diagnosed. In addition, in some areas dense and fibrous connective tissue that acted as an impediment to tooth eruption was observed. Some authors^[4] also described a chronic inflammatory gingival overgrowth combined with APE clinical case. Those authors indicated gingivectomy as a treatment for these cases. APE produces an anti-aesthetic effect known as gummy smile and also prevents the placement of orthodontic appliances^[5]. Gottlieb and Orban (1933)^[5] had already defined passive eruption as a normal and necessary displacement of the junctional epithelium in apical direction until it reaches the cement-enamel junction (CEJ). It

was reported that patients with altered passive eruption presented short crowns due to the gingival margin not having migrated to their final position in the apical direction^[6]. Foley et. al. (2003)^[7] pointed out that young patients that required orthodontic treatment needed a previous diagnosis and periodontal treatment in cases involving excessive gingival display (Altered Passive Eruption - APE) and gingival fibrosis (hyperplasia) which interfered with the teeth aesthetics and might have fully prevented or delayed permanent tooth eruption. The purpose of presenting this case is to show that an aesthetic result can be achieved by means of resection of periodontal surgery, aiming at aesthetic, maintenance of healthy periodontium, in a patient with gingival hyperplasia antero superior.

Literature Review

Gingival alterations, either in acute or chronic nature, are nearly universal among children and adolescents. Diagnosis of various types of gingivitis relied mainly on the clinical findings and manifestations^[2]. Gingivitis, a reversible dental plaque-induced inflammation of the gingiva, is a common occurrence in children. Gingivitis is common, especially around puberty affecting over 80% of young children while almost the entire population experiences gingivitis, periodontitis or both^[8].

Gingival overgrowth or gingival enlargement (also known as gingival hyperplasia) is one of the frequent features of gingival diseases and can be caused by gingival inflammation, fibrous overgrowth or a combination of the two^[9]. It may be plaque induced, associated with hormonal or systemic disturbances, drug induced, etc. and different forms of enlargement have different clinical and histological presentations and thus proper history taking, clinical and histopathological examination is the key in differentiating one type of enlargement from the other and also for establishing an accurate diagnosis and formulating a proper treatment plan^[10].

Mavrogiannis et. al., (2006)^[11] pointed out that the nature of the relationship between plaque and the expression of gingival overgrowth is unclear, and, controversy exists as to whether plaque accumulation is the cause of the gingival changes or the consequence

Citation: Gisele Fernandes Dias et al. (2019), Gingival Overgrowth and Altered Passive Eruption in Adolescents: Literature Review and Case Report. Int J Dent & Oral Heal. 5:1, 09-12

of it. Kataoka et. al. (2005)^[12] affirms that gingival fibrous overgrowth is characterized by the accumulation of extracellular matrix in gingival connective tissues, particularly collagenous components with various degrees of inflammation. Although the mechanisms of these disorders have not been elucidated, recent studies suggest that these disorders seem to be induced by the disruption of homeostasis of collagen synthesis and degradation in gingival connective tissue, predominantly through the inhibition of collagen phagocytosis of gingival fibroblasts. APE is another clinical condition observed in the anterosuperior region in this case report. Tooth eruption normal process (active eruption) must be followed by some movement of the soft tissue (passive eruption), in which the gingival margin (or dentogingival unit) must migrate apically up to the cement-enamel junction^[13]. When this tissue migration does not occur, the gingiva remains static and covering part of the tooth crown which leads to APE. The excess gingival display or gummy smile is observed clinically and usually involves young patients. The occurrence of APE is unpredictable, but the frequency in the general population is about 12%. The gingiva of any patient with altered passive eruption is usually healthy in the absence of plaque^[6].

Piatelli and Eleuterio (1991)^[14] described the causes that might lead to failure in tooth eruption such as root ankyloses, cists, supernumerary teeth, tumors and soft tissues (gingival fibrosis). They also include APE as a factor that might delay tooth eruption and hamper the placement of orthodontic appliances. Suri, Gagari, and Vastardis (2004)^[15] pointed out that an orthodontic treatment plan requires periodontal consultation to manage gingival fibrosis (or hyperplasia) and the excessive gingival display (Altered Passive Eruption).

Coslet et al. (1977)^[6] proposed a classification of APE and evaluated the relationship between the gingiva and the clinical crown on one hand and the relationship between the CEJ and the bone crest on the other. Their classification was subdivided as follows:

Type I: the gingival margin is incisal to the CEJ, the dimension of keratinized gingiva is wider than usual, and clinical crowns are short.

Type II: the dimension of the gingiva from the gingival margin to the mucogingival junction appears normal. The free gingival margin is incisal or occlusal to the CEJ and the mucogingival junction is positioned at the CEJ.

Subtype A: the alveolar crest distance to CEJ is approximately 1.5mm:

in such cases a normal attachment (biological width) can be found.

Subtype B: the alveolar crest is at the level of the CEJ or above.

The passive eruption normal condition should result in the cement-enamel junction location approximately on the sulcus base and 2mm from the alveolar bone crest. The distance, called biological width, from the alveolar crest to the base of the sulcus is commonly around 2 mm: 1 mm of epithelial attachment and 1 mm of connective tissue attachment¹⁶. Aiming at diagnosing the APE type, measurements are recommended, under anesthetics, of the relation between the CEJ and the alveolar crest¹⁸. The APE treatment – gingivectomy or periodontal flap with bone resection¹⁷ – is carried out based on these measures.

In APE, the type of surgical procedure to be used depends on several factors. After evaluation of whether the bone level is appropriate and whether there is around 2 mm of tissue from the bone to the gingival tissue crest and only when it is determined that a proper zone of attached gingiva will remain after surgery, a gingivectomy is indicated¹⁸. This procedure applies to cases of gingival overgrowth and Altered Passive Eruption type 1A¹⁷.

Case report

A 14-year old male presented with a chief complaint of 'short teeth'. Excessive gingival display was observed on the maxillary anterior teeth which harmed dental aesthetics and prevented the placement of orthodontic appliance (Figure 1). After a comprehensive clinical facial and dentogingival examination, the cement enamel junction was confirmed to be undetectable clinically and the patient was diagnosed with Altered Passive Eruption (Coslet Type 1 A). The patient was also diagnosed with chronic inflammatory gingival overgrowth¹ in the mandibular anterior teeth (Figure 1).

Several permanent teeth were prevented from erupting due to the dense and fibrous connective tissue that acted as an impediment to the eruption of canines and second molars (Figure 2). Figure 3 shows the gingivectomy post-operative with a zone of attached gingiva that remained after surgery. Figure 4 displays: A) gingival biopsy with the keratinized oral epithelium and B) the histopathological analysis. Figures 5 and 6 show the post-operative with the aesthetic results expected and Figure 7 shows the panoramic radiographs revealing the eruption of permanent teeth after surgical removal of the fibrous connective tissue.

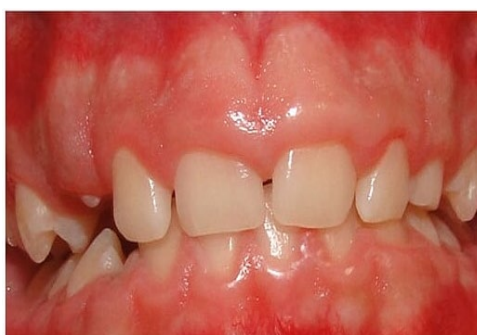

Figure 1: Altered Passive Eruption (superior teeth) With excessive gingival display and chronic inflammatory gingival overgrowth (inferior teeth). Short clinical crowns can be observed

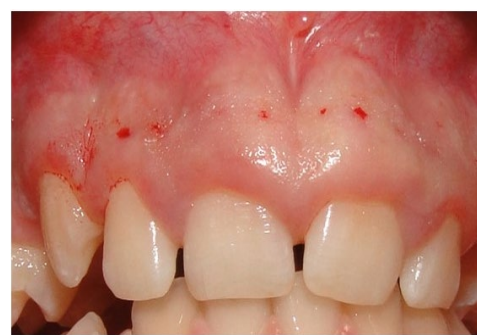

Figure 2: For the diagnosis of the EPA type, the use of measurements, under anesthetics, of the relation between the cement-enamel junction -CEJ and the alveolar crest is recommended (Figure 2)

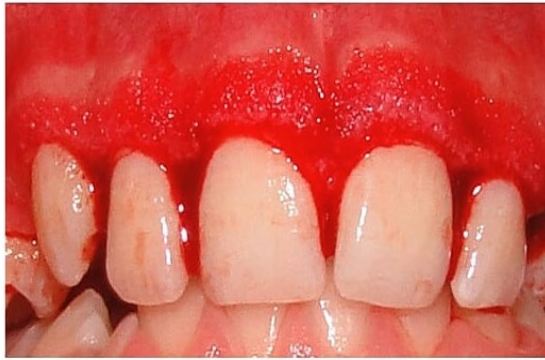

Figure 3: Gingivectomy-immediate post operative . This case belongs to the Costlet type 1A, in which the bone level is appropriate , if there is around 2 mm tissue from the bone to the gingival tissue crest and if it determined that an adequate zone of attached gingiva will remain after surgery

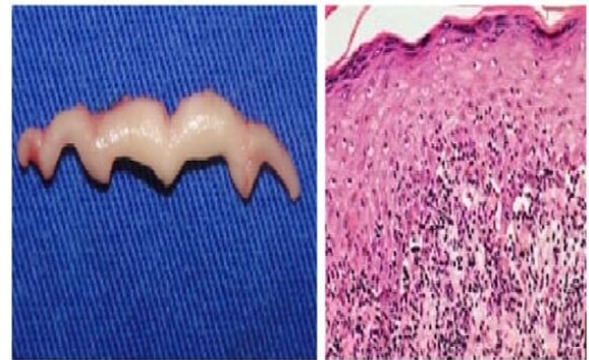


Figure 4: Gingival biopsy in A) the keratinized oral epithelium is observed ; in B) histopathological analysis

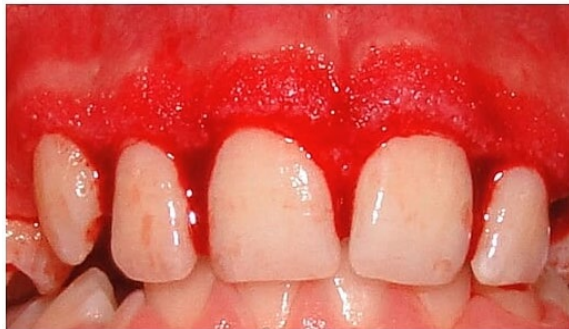

Figure 5: Post -operative images after 30 days

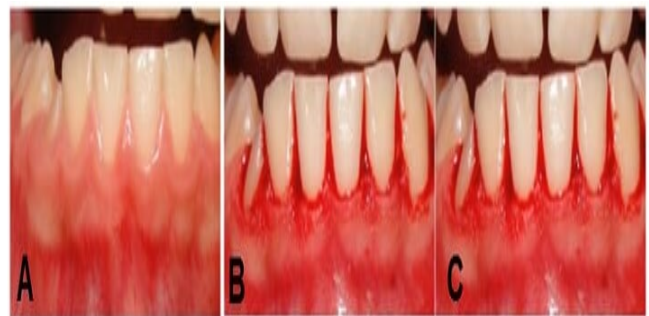


Figure 6: Gingivectomy in the mandibular region. In A) a chronic inflammatory gingival overgrowth; in B) immediate post-operative and in C) after 60 days

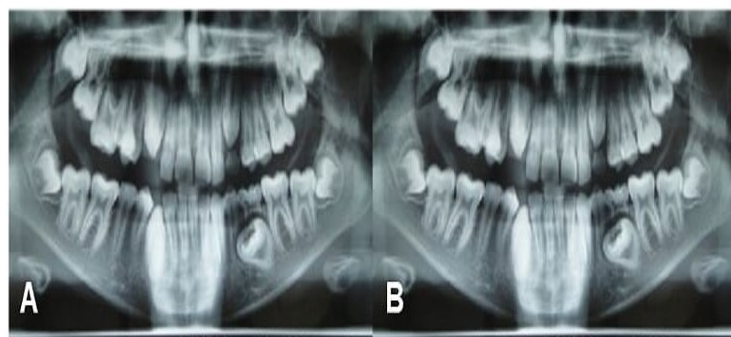


Figure 7: (A) Pre-operative panoramic radiograph; and (B) after 60 days. Note (in B) the eruption of some permanent teeth after the resective surgical procedures

Discussion

Some authors have demonstrated the coexistence in the same patient of chronic inflammatory gingival overgrowth and Altered Passive Eruption – APE. Diagnosed with different etiologies, these gingival alterations might, however, be combined^[4]. Gingival overgrowth not only interferes with the smile aesthetics, but can also take over a mechanical role that prevent teeth from erupting. Gingivectomy is the treatment of choice in such cases, and it can be performed by a conventional method with periodontal knives^[18].

Authors recommend periodontal therapy prior to the orthodontic treatment, in young patients, mainly those presenting gingival enlargement (hyperplasia), fibrous tissue overlying the crown (that prevents tooth eruption) and excessive gingival display (Altered Passive Eruption), since these clinical conditions might damage the patient's aesthetics. In addition, the placement of orthodontic appliances becomes unfeasible in regions where the clinical crown is covered by gingiva^[7,15,3].

The normal eruption of permanent teeth might also be delayed due to the presence of an abundance of dense connective tissue that can be an impediment to tooth eruption³. In such cases, surgical exposure of a tooth facilitates its eruption and allows the orthodontic treatment to be completed in a timely manner. In most cases, the canine teeth and second molar teeth need to be surgically exposed due to delayed eruption. Excision of the dense fibrous tissue facilitated the further eruption^[19].

Except for its esthetic consequences, several authors consider that Altered Passive Eruption is a risky situation for the periodontal health. Indeed, difficulties in oral hygiene and narrow connective attachment are both highlighted¹⁸. Altered passive eruption is well described in the literature and the surgical solutions are well known. The type of periodontal surgical procedure depends on a number of factors. If the bone level is appropriate, if there is more than 2 mm of tissue from bone to gingival crest and if it is determined that an adequate zone of attached gingiva will remain after surgery, a gingivectomy with Kirkland and Orban instruments is indicated^[20,21].

If the diagnostic procedures reveal bone levels approximating the CEJ, a gingival flap with osteotomy is indicated. A full-thickness flap is reflected beyond the mucogingival junction, and the positions of the CEJ and crestal bone are verified visually^[21]. Osteotomy is then performed so that the crestal bone is approximately 2.5 to 3.0 mm from the CEJ, which provides for a biologic width that is physiologically adequate^[16]. Gingivectomy is a very successful and predictable surgical procedure for reconstruction of biologic width, but it can be used only in situations with gingival enlargement (hyperplasia), Altered Passive Eruption or pseudopocketing as a disorder in which there has not been significant violation of the biologic width^[4,17,20].

Conclusion

Both the aesthetic result periodontal health were achieved, confirming the efficacy of the resective surgery as an adjunct to the adequacy of gingival aesthetics and maintenance of the periodontium healthy.

References

1. Carranza FA, Hogan EL. Gingival enlargement. In: Newman MG, Takei HH, Klokkevold PR, Carranza FA. *Carranza's Clinical Periodontology*. 10th ed. Philadelphia, Penn: W.B. Saunders Company; 2006:373–390.
2. Al-Ghutaimel, H., Riba, H, Al-Kahtani, S., Al-Duhaimi, S. Common Periodontal Diseases of Children and Adolescents. Review Article. *Int J Dent*. 2014;850674, 1-7.
3. Pulgaonkar R.; Chitra P. *Altered Passive Eruption Complicating Optimal Orthodontic Bracket Placement: A Case Report and Review of Literature*. *J Clin Diagn Res*. 2015 Nov; 9(11):1-3.
4. Garber DA, Salama MA. *The aesthetic smile: diagnosis and treatment*. *Periodontol* 2000. 1996 11:18-28.
5. Gottlieb B, Orban B. Active and continuous passive eruptions of teeth. *J Dent Res*. 1933;13:214.
6. Coslet JG, Vanarsdall R, Weisgold A. Diagnosis and classification of delayed passive eruption of the dentogingival junction in the adult. *Alpha Omegan*. 1977. 70:24-28.
7. Foley, T. F.; Sandhu, HS; Athanasopoulos, C. *Esthetic Periodontal Considerations in Orthodontic Treatment — The Management of Excessive Gingival Display*. *Journal of the Canadian Dental Association* 2003, 69(6):368-72.
8. Hugar, SM, Deshpande, SD, Shigli, A, Reddy, R. *An Overview of Gingival and Periodontal Diseases in 12 to 15 years using Gingivitis and Periodontitis Site Prevalence Index (WHO, 1978)*. *World Journal of Dentistry*, July-September 2011;2(3):175-181.
9. Goldman HM, Cohen DW. *Periodontal therapy*. 4th ed. St. Louis: Mosby; 1968.
10. Dholakia P, Patil U., Agrawal C, Chokshi R, Patel D, Nayak R. *Management of Puberty Associated Gingival Enlargement in the Aesthetic Zone in an Adolescent Female- A Case Report*. *Int J Oral Health Med Res* 2016;2(5):96-98.
11. Mavrogiannis M, Ellis JS, Thomason JM, Seymour RA. *The management of drug-induced gingival overgrowth*. *J Clin Periodontol*. 2006 Jun;33(6):434-9.
12. Kataoka, M., Kido, J, Shinohara, Y., Nagata, T. *Drug-Induced Gingival Overgrowth—a Review*. *Biol. Pharm. Bull.* 2005; 28(10):1817—1821.
13. Silberberg N, Goldstein M, Smidt A. *Excessive gingival display—etiology, diagnosis, and treatment modalities*. *Quintessence Int*. 2009 Nov-Dec;40(10):809-18.
14. Piattelli A, Eleuterio A. Primary failure of eruption. *Acta Stomatol Belg*. 1991;88:127-30.
15. Suri, L. Gagari, E., Vastardis, H. *Delayed tooth eruption: Pathogenesis, diagnosis, and treatment. A literature review*. *American Journal of Orthodontics and Dentofacial Orthopedics* 2004;126 (4), 432-445.
16. Schmidt JC, Sahrman P, Weiger R, Schmidlin PR, Walter C. *Biologic width dimensions—a systematic review* *J Clin Periodontol*. 2013 May; 40(5):493-504.
17. Rossi, R., Brunelli, G., Piras, V., Pilloni, A. *Altered Passive Eruption and Familial Trait: A Preliminary Investigation*. *Int. Jour of Dentistry* 2014; 874092, 1-5.
18. Dolt AH, Robbins JW. *Altered passive eruption: an etiology of short clinical crowns*. *Quintessence Int*. 1997, 28(6):363-72.
19. Shah, SB; Kulkarni, G. *Guiding Unerupted Teeth into Occlusion: Case Report*. *J Can Dent Assoc* 2010;76:a147.
20. Alpiste-Illueca, F. Altered passive eruption (APE): A little -known clinical situation. *Med Oral Patol Oral Cir Bucal*. 2011 Jan 1;16 (1):100-4.
21. Mele M, Felice P, Sharma P, Mazzotti C, Bellone P, Zucchelli G. *Esthetic treatment of altered passive eruption*. *Periodontol* 2000. 2018;77(1):65-83.