

Synergetic Dental Fixed Bridges

R.S. Carlson DDS

Inventor of the Carlson Bridge®, Honolulu, Hawaii, USA

Corresponding Author: R.S. Carlson, Inventor of the Carlson Bridge®, Honolulu, Hawaii, USA. Email: ddscarlson@hawaiiantel.net

Citation: R.S. Carlson (2017), Synergetic Dental Fixed Bridges. R.S. Carlson DDS Int J Dent & Oral Heal. 3:8, 78-81.

DOI: [10.25141/2471-657X-2017-8.0065](https://doi.org/10.25141/2471-657X-2017-8.0065)

Copyright: ©2017 R.S. Carlson. This is an open-access article distributed under the terms of the Creative Commons Attribution License, which permits unrestricted use, distribution, and reproduction in any medium, provided the original author and source are credited

Received: September 13, 2017; **Accepted:** September 21 2017; **Published:** October 25, 2017

Introduction

Old hands in dentistry know the value they create in rebuilding dentitions (mouths) by replacing missing and broken teeth, their contributions in time and money for their patients. They are also aware of the costs of maintaining a modern dental practice on an hourly basis. This “hourly basis” is just one standard upon which dentists base their fees that work together with other expense factors and value offered/created.

Let us look at one procedure, the single tooth fixed replacement of a missing tooth, to demonstrate the synergetic impact of modern dental materials and processing times in a new fixed bridge innovation—**Carlson Bridge® “Winged Pontic” Tooth Replacement Systems**.

We define **synergy** as:

1. The interaction of elements that when combined produce a total effect that is greater than the sum of the individual elements, contributions, etc.; synergism.
2. Physiology, Medicine/Medical. The cooperative action of two or more muscles, nerves, or the like.
3. Biochemistry, Pharmacology. The cooperative action of two or more stimuli or drugs.

This principle in life, synergy, is observable in this true life example: during World War II, the search for lightweight, super-strong, durable and easily worked with metals for the production of airplanes was of prime importance. What scientist found in trial and error chemical structuring of metals such as iron, steel, cobalt, aluminum, etc., was that often the strengths of the end products combined were 5 to 10 time greater than expected. They anticipated a result that might have been expected of a tensile strength 10,000 lbs. / inch². ; but, what resulted from this combination was 100,000 lbs./inch².

Baffled by this the aerospace industry termed this phenomenon synergy as they called upon “Bucky” for clarification. R.B. Fuller (Bucky) wrote about this extensively in his book SYNERGETICS published in 1975. Other scientific researchers called it “doing more with less or more with less-ing.”

We meet with “synergy” every day of our lives little aware of its profound impact. In a sense Synergy is Creativity, the act of experimentation and thoughtfulness as to a vision of a much better service we may offer the dental patient.

We present this principle, synergy, as observed in the profession of dentistry as demonstrated in **Table 1**.

	Removable flipper	Traditional bridge	Dental Implant	Carlson Bridge®
Cost	~\$1,740.00	~\$4,500.00	~\$6,400.00	~\$1,600.00
1. No. of Visits	2-3	3-5	12-20	1
2. Definitive Result	No	Yes	Yes	Yes
3. Approx. Lifespan	6 mo.—1yr.	3—5yrs.	?	3—5yrs.
4. Tissue Altered	Little	Yes	Yes	None
5. Completion time	1—2 Weeks	About 1 month	6mo.—1 year	One Day
6. Time in chair	1 hour	3—6 hours	5—15 hours	1 hour
7. Expected pain	No	Moderate to High	Moderate to High	No
8. Needed meds	No	Yes	Yes	No
9. Easily modified	No	No	No	Yes
10. Shade modified	No	No	No	Yes-Anytime
11. Laboratory Costs	Yes	Yes—High	Yes—Very High	None
12. Stress Doctor	Very little	Very High	Very High	Little/ Moderate
13. Galvanic Current (Clasps) -2-3uA	(Clasps) -2-3uA	(Metal) -3-12uA	(Tit.)-30-200uA ¹	None
14. Stress Patient	Little	Moderate/High	Very High	Little / None
15. Death Threat	None	Moderate	Moderate to High	None

Table 1. Single Tooth Synergetic Replacement Comparison ^(1,2,3)

What Carlson Bridge® Technologies has shown since 1999 that a fixed dental bridge of very high standards and quality can be done in as little as an hour with restorative dental composites of superior structure without internal fiber support as proposed by many companies, and a new conceptioning. ^(4,5,6,7,8,9,10)

Case Study of Synergy in Dentistry

An 82year old man split tooth #12 and came to us to correct his missing tooth issue. He had heard of our tooth replacement process and wanted it done rather than extensive tooth reduction for a traditional bridge or implant placement for a crown. His physical condition prohibited long sessions in the chair since he had spinal scoliosis.

In view of his requirements we accomplished the following steps as demonstrated in the photos as follow in one hour.

In photo 1 a missing left first premolar, tooth #12 is seen. The prefabricated “Winged Pontic” is seen in photo 2 having been adjusted for the edentulous space.

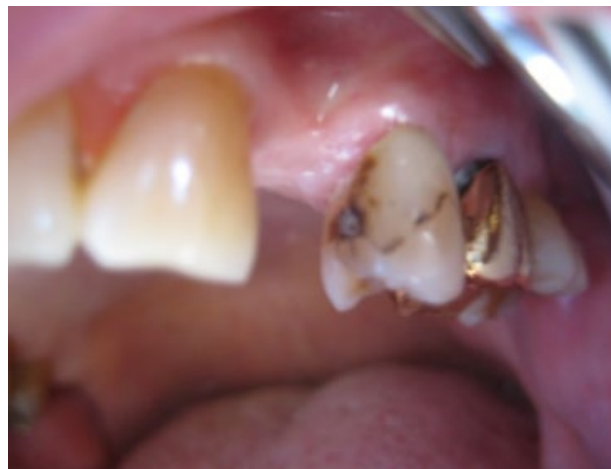Photo 3 shows occlusal relationships of the prefab “Winged Pontic,” trimmed and adjusted into the space between the support teeth without attachment composite affixed. The line of placement is confirmed as the “Winged Pontic” is adjusted to flow in and out of the space easily.

Photo 4 shows the “Winged Pontic” first premolar #12 with attachment composite applied to the proximal surfaces ready for insertion between #11 and #13, but only after preparation of the support teeth #11 and #13 for decay and surface cleanliness. After treating the enamel of support teeth #11 and #13 with etchant, water cleaning and drying, old existing composites are silanated with Carlson Bridge® “Winged Pontic” Bond Enhancer and then a coat of clear resin and attachment composite are applied to proximal surfaces seen in Photo 5.

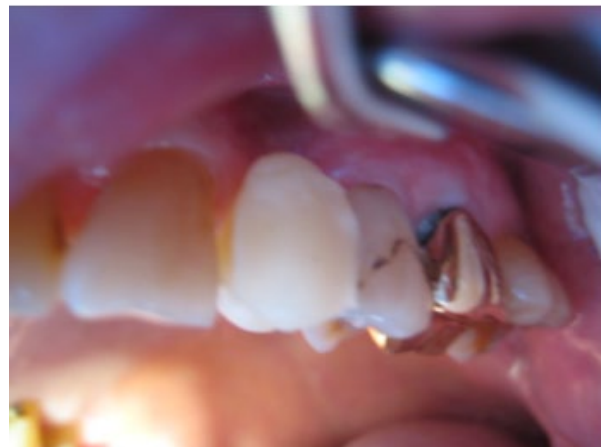The prefab “Winged Pontic” (Photo 4) has first been etched for 30 seconds, cleaned with water, next treated with the CB® “WP” Bond Enhancer, clear resin is applied, followed by attachment composite application to proximal surfaces as seen in Photo 4. The “Winged Pontic” is now ready for insertion between the support teeth seen in Photo 5.

The prefabricated, pretreated “Winged Pontic” is carried to the space and inserted as seen Photos 5 and 6 in the predetermined line of draw. The attachment composite is smoothed over all aspects of the pontic and support teeth and then light cured. The “Winged Pontic” is layered over with finishing composite, if needed. This is a time when creative artistic skills may be applied. Once cured, the occlusion is checked and adjusted in all excursions. Various flame shaped finishing diamonds are used for characterization. Final polish may be done with fine finishing diamonds 25 micron and 50 micron, and rubber wheels. Final results are demonstrated in Photos 7 and 8.

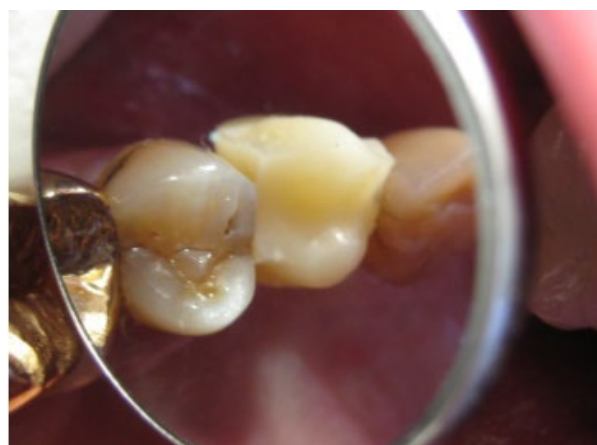1) Pre-op showing slight decay on mesial of #13 with a cervical composite restoration on the facial aspect.



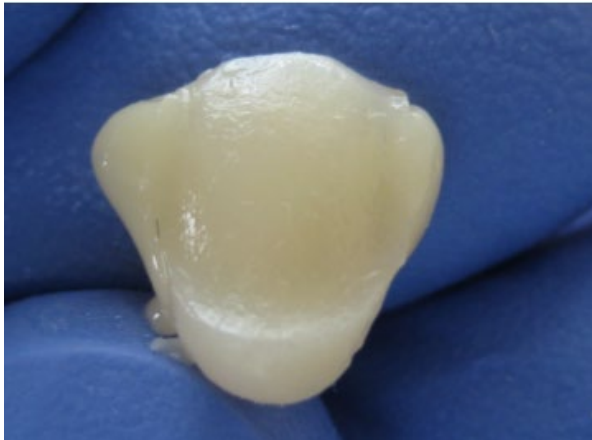
2) The “Winged Pontic” is shown after fitting into the edentulous area



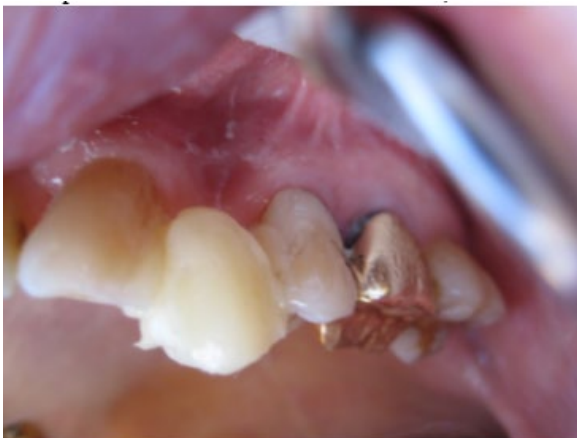3) Occlusal view of loose fitting “Winged Pontic”.



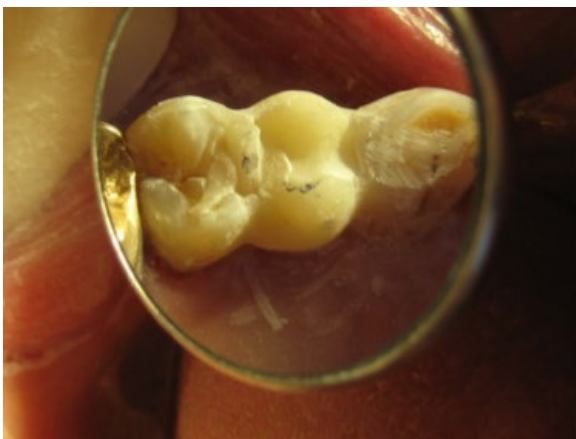4) “Winged Pontic” prepared for installation with soft composite on proximals.



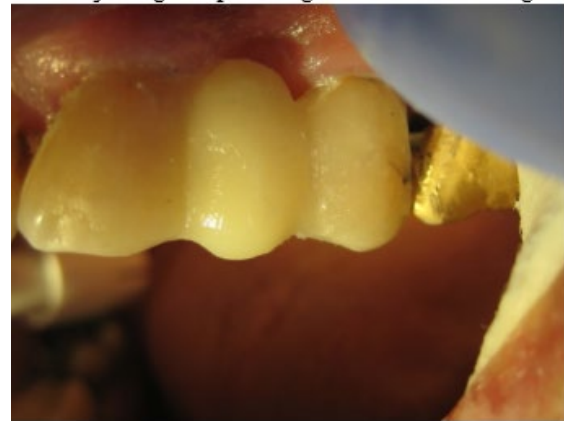5) Once proximals of #11 and #13 are readied, the “WP” is installed.



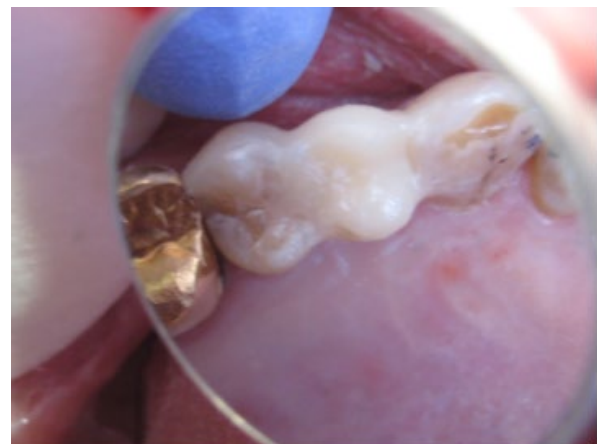6) Once full insertion complete curing takes place and adjusting begins



7) Final adjusting and polishing of the Carlson Bridge® “Winged Pontic.”



8) Occlusal view of the finished composite bridge.



Our Possible Futures

This process, the Carlson Bridge® “Winged Pontic” tooth replacement system may open doors to new possibilities in the way dentists practice.(12,13) Biosynthetic tissue engineering seems to be the leading edge in dentistry today, but only as an adjunct to other technical procedures carried out in the dental office, such as implants, flippers, or traditional porcelain veneer bridges. Resin composite materials are the closest to dentine and enamel in their strengths witnessed by their flexural modulus, compressive strengths and wear capacities

With this new methodology, it may also be a pleasant experience for the patient who can shorten his or her time in the dental chair and come away with an immediate dental cosmetic enhancement. Additionally, it will not create a financial burden or, require extensive healing time or unnecessary oral discomfort.

It is also beneficial to the dental practitioner since the procedure is shorter in duration, therefore physically less demanding, less complicated in that intricate tooth preparations are unnecessary, and ultimately more rewarding creatively, artistically and remuneratively.

Conceivably a well trained dental hygienist or dental assistant could complete this tooth replacement in less complicated and challenging areas. Overseen by the dental surgeon, the fixed bridge results would be ensured as to strengths, dynamics of occlusion and esthetics. This may in the future be a norm for some practices in maintaining his or her viability in the market place of dentistry facing growing “corporate dentistry” and the general changes in our society relative to finance, productivity and profit.

As with the new restorative composite systems of direct composite restorations the “Winged Pontic” prefab system offers a choice for the doctor and the patient regarding complex treatment plans and procedures. In this day and age of limited dental health budgets, it is an idea whose time has come.

In senior populations health issues as well as costs are a major consideration in replacement of missing teeth. We have perfected the methodology for a one appointment, minimal time in the chair, direct composite bridge we identify as the **Carlson Bridge® “Winged Pontic” tooth replacement system** for one or more missing teeth.(13)

We present this short article with the intention of encouraging others to use this non-invasive, artistically satisfying and relatively inexpensive system not only for seniors, special needs people, but in young and middle age people as well.

References

1. Gittens, R.A. et al, [Electrical Implications of Corrosion for Osseointegration of Titanium Implants](#), J Dent Res 90(12): 1389-1397, 2011
2. Valle, A. et al, [Effects of low electrical currents \(LEC\) treatment of pure bacterial cultures](#), Journal of Applied Microbiology ISSN 1364-5072, 2007
3. Palmer, SB, MDS, “SECONDARY” DECAY, The Dental cosmos; a monthly record of dental science: Vol. XXII. [Vol. 22] Title: “Secondary” Decay. [Volume 22, Issue 1, January, 1880, pp. 15-21]
4. Jokstad A, Gokce M, Hjortsjo C. [A systematic review of the scientific documentation of fixed partial dentures made from fiber-reinforced polymer to replace missing teeth](#). Int J Prosthodont. 2005;18:489-496.

5. Carlson, RS, D.D.S., “Breakthrough Dental Bridgework: The Bio-Logical Dental Bridge,” Dentistry Today, 1999, Volume 18, No. 1, pages 88-93.
6. Carlson, Ronald S., D.D.S., “Dental Artistry,” General Dentistry, The PeerReviewed Journal of the Academy of General Dentistry, July-August 2003; Vol. 51, No. 4.
7. Carlson, RS, D.D.S., [Cap it? Or Wrap it? Dentistry Today. 2009; Volume 28, No. 6, pages 74-75.](#)
8. Belvedere, P., D.D.S., Turner, W. E., D.M.D., “Direct Fiber-Reinforcement Composite Bridges” Dentistry Today, Volume 21, No. 6, page 88-94.
9. Knight JS, Whittaker DA. [A new look at chair-side fiber reinforcement of resin composite](#). Gen Dent. 2003; 51:334--336.
10. Carlson RS. [Immediate Post-Extraction In Situ Direct Lamination Composite Bridge](#). Dent Today. 2006; 25:116-119.
11. van Heumen CC, Kreulen CM, Bronkhorst EM, Lesaffre E, Creugers NH. [Fiberreinforced dental composites in beam testing](#). Dent Mater., 2008 Nov;24(11):1435-43. Epub 2008 Aug 9.
12. Bayne SC, Ph.D., [Dental Biomaterials: Where are We and Where Are We Going?](#) J. Dent Ed., May 2005; Vol. 69 no. 5, 571-585.
13. Carlson RS. [Preformed Design Bridging Concept: A Case Report](#) Dent Today. 2014 July; Vol.33 No.7: 124-127.

Dr. RS Carlson graduated from the University of Michigan School of Dentistry in 1969 and completed Post Graduate training in pediatric dentistry with Strong-Carter Dental Clinic, Honolulu, Hawaii, 1970—71. He is a founder of Kokua Kalihi Valley Dental Clinic in 1973 (<http://www.kkv.net/index.php/history>) and volunteered from 1973 to 1980 serving low-income families and immigrant populations from the South Pacific Islands and Asia. He has maintained a private practice in Honolulu since 1971 emphasizing Bio-Logical Dentistry. He can be reached at (808) 735-0282, ddscarlson@hawaiiantel.net or carlsonbiologicaldentistry.com. Disclosure: Dr. Carlson is the inventor of the Carlson Bridge® “Winged Pontic” tooth replacement system, a noninvasive approach to replacing missing teeth, with patents issued in November